

Diazinon-Induced Ovarian Toxicity and Protection by Vitamins E

Zinat Sargazi¹, Mohammad Reza Nikravesh*¹, Mehdi Jalali¹, Hamid Reza Sadeghnia², Fatemeh Rahimi Anbarkeh¹, Leila Mohammadzadeh³

Received: 03.03.2014

Accepted: 23.04.2014

ABSTRACT

Background: DZN (diazinon) is an organophosphate insecticide that had been used in agriculture and for domestic and veterinary use for several years and caused many negative effects on plants and animal species, especially on human. The aim of present study was to evaluate the effects of DZN on MDA (malondialdehyde) and GSH (glutathione) levels in female rat reproductive tissue (ovary) and to assess the protective role of vitamin E.

Methods: A total of 30 adult female Wistar rats were divided into five groups: control group (without any intervention), sham group (received only pure corn oil, as solvent), experimental group 1 (DZN+corn oil, 60 mg/kg), experimental group 2 (vitamin E, 200 mg/kg), and experimental group 3 (DZN+vitamin E, the same dosage). All drugs were injected intraperitoneally, except vitamin E which was administrated by gavage. The animals were scarified after two weeks and MDA as a marker of lipid peroxidation and GSH content were measured in ovarian tissue.

Results: DZN reduced GSH content and increased MDA level in ovary compared with the control group ($P < 0.001$). Vitamin E plus DZN increased GSH content but decreased DZN-induced MDA elevation in rat ovarian tissue.

Conclusion: Oxidative stress contributes to DZN-induced ovarian toxicity. The results of this study suggested that vitamin E may have a protective effect on DZN-induced ovarian toxicity.

Keywords: Diazinon, Glutathione, Malondialdehyde, Ovary, Vitamin E.

IJT 2014; 1130-1135

INTRODUCTION

Pesticides and herbicides are persistent and dangerous chemical compounds that are used extensively in agriculture to enhance food production. Among them, pesticides organophosphates are commonly used as insecticides. They are generally the most toxic pesticides for animal species, especially vertebrate animals [1]. Organophosphorus compounds have been utilized in agriculture, industry, medicine, farming, animal keeping, and households to kill insects, worms, nematodes, fungi, and weeds for five decades [2-5].

Unfortunately, the improper use of these products damages the environment- plants, animals, soil, and water- and creates resistance to them which is an increasing concern in this field [6,7]. Residual amounts of organophosphate insecticides are detectable in soil, tissues of organisms, vegetables, grains, and other foods products [7]. On the other hand, it

has been reported that organophosphate insecticides negatively affect different tissues, including liver, kidney, immune system, pancreas, and cardiac and vascular walls, and induce hematological and biochemical changes. One of the affected organs is the ovary, which has a key role in reproductive function by synthesizing hormones and producing oocyte [8, 9]. DZN (0,0-diethyl-0-[2-isopropyl-6-methyl-4-pyrimidinyl] phosphorothioate) is a pesticide with a wide range of action which inhibits acetylcholinesterase (AChE) activity. It has been widely used throughout the world with applications in agriculture and horticulture for controlling insects in crops, ornamentals plants, lawns, fruits, vegetables, and food products. It is also used as a pesticide in household and agricultural public health, and for veterinary purposes [3, 7, 10-12]. Research has shown that DZN can be absorbed through the digestive system, skin, or via the respiratory mucosa when inhaled [13]. In addition to its inhibitory effects

1. Department of Anatomy and Cell Biology, Mashhad University of Medical Sciences, Mashhad, Iran.

2. Department of Pharmacology, Mashhad University of Medical Sciences, Mashhad, Iran.

3. Department of Pharmacodynamics and Toxicology, Mashhad University of Medical Sciences, Mashhad, Iran.

*Corresponding Author: E-mail: nikraveshmr@mums.ac.ir

on AChE, it can increase formation of free radicals and so induce oxidative stress and tissue lipid peroxidation in mammals and other organisms [14,15].

Reactive Oxygen Species (ROSs) are part of normal oxidative metabolism, but they can cause tissue damage as lipid peroxidation when produced in large amounts [16]. MDA is a major oxidation product of peroxidized polyunsaturated fatty acids and elevated MDA content is a significant indicator of lipid peroxidation [7,14]. Thiol groups are sensitive to oxidative damage and normally decrease in response to oxidative stress [17]. GSH is one of the thiol groups that has an essential role in protecting cells from damage induced by oxidative stress [18].

Antioxidants, on the other hand, are scavengers that detoxify excessive ROS and play an important role in maintaining oxidant/antioxidant balance in the body. Antioxidants are of two types: enzymatic and nonenzymatic [15]. Vitamin E (α -tocopherol) is a family of lipid-soluble vitamins and acts as an antioxidant in cells by protecting cellular membranes and lipoproteins from peroxidation. In addition, several studies have shown that α -tocopherol inhibits free radical formation and so decreases lipid peroxidation in biological systems [5]. The aim of this study was to investigate the effects of DZN, an organophosphate insecticide, on MDA and glutathione levels and evaluate the protective role of vitamin E in rat ovarian tissue.

MATERIALS AND METHODS

Animals

A total of 30 adult female Wistar rats were obtained from the Animal Lab of Mashhad University of Medical Sciences, Mashhad, Iran. The animals were divided into five groups: control (without any intervention), sham group (received only pure olive oil, as solvent), experimental group 1 (DZN+ olive oil, 60 mg/kg), experimental group 2 (Vitamin E, 200 mg/kg), and experimental group 3 (DZN+vitamin E, with the same dose). In this study, olive oil was used as solvent. DZN and solvent were administrated by intraperitoneal injection and Vitamin E was given by gavage. All of these animals were scarified after two weeks and MDA, as a marker of lipid

peroxidation, and GSH content were determined in ovarian tissues.

Chemicals

DZN was diluted in olive oil. Malondialdehyde, thiobarbituric acid, Malondialdehyde tetrabutylammonium, reduced glutathione (GSH), DTNB [**5,5'-Dithiobis(2-nitrobenzoic acid)**] and vitamin E (α -tocopherol acetate) were purchased from Sigma Co.

Lipid Peroxidation Test

The amount of lipid peroxidation was assessed through the measurement of MDA levels in ovarian tissues. MDA reacts with thiobarbituric acid (TBA) and produces a pink colored complex which has the maximum absorbance at 532nm. Initially, 3 ml of phosphoric acid (1%) and 1 ml of TBA (0.6%) were added to 10% homogenated tissue in KCl and, then, the compound was heated for 45 min in a boiling water bath. After cooling the compound, 4 ml of n-butanol was added to it and vortex-mixed was used for 1 min followed by centrifugation at 3000 g for 10 min. After that, the organic layers were removed and transferred to other tubes and absorbance level was read at 532 nm [19]. A calibration curve was designed using Malondialdehyde tetrabutylammonium. MDA levels were expressed by nmol/g tissue.

Reduced Glutathione (GSH) Examination

GSH was evaluated in ovarian tissue through the method employed by Moron *et al.* [20]. The basis of this was the formation of yellow color after adding DTNB [**5,5'-Dithiobis(2-nitrobenzoic acid)**] to compounds containing sulfhydryl groups. For this purpose, 300 μ l of homogenates tissues was blended with 300 μ l of 10% tricoloroacetic acid (TCA) and vortexed. After centrifugation at 2500 g for 10 min, the upper layers were removed and blended with reaction mixtures containing 2 ml phosphate buffer (pH: 8) and 500 μ l DTNB. After 10 min, the absorbance was evaluated at 412 nm using a spectrophotometer (Jenway 6105 uv/vis, UK). At the end of this process, the amount of GSH was determined based on a standard curve drawn with commercially available GSH and GSH Levels were expressed by nmol/g tissue.

Statistical Analysis

Results are expressed as mean \pm SD. Statistical analysis was performed with ANOVA

followed by Tukey–Kramer test to compare the differences between means. Differences were considered statistically significant at $P < 0.05$.

RESULTS

Effect of Vitamin E on Ovary Lipid Peroxidation Induced by Diazinon

The results of the present study indicated that MDA level significantly increased in the DZN treated group compared to the control group ($P < 0.001$). MDA level decreased significantly in vitamin E+DZN-treated group compared with the DZN group. Administering vitamin E (200 mg/kg) alone also significantly decreased the level of MDA compared with DZN treated rats ($P < 0.001$). Administration of vitamin E (200 mg/kg) and oil (60 mg/kg) alone

had no significant effects on the MDA content compared to control group (Figure 1).

Effect of Vitamin E on GSH Content in Ovarian Tissue Following Exposure to Diazinon

The results also revealed significant decreases in GSH content in the DZN-treated group compared with the control group ($P < 0.001$). GSH content increased significantly in the vitamin E+DZN-treated group compared with the DZN group ($P < 0.01$). Administering vitamin E (200 mg/kg) alone significantly increased the GSH content in comparison with the DZN treated rats ($P < 0.001$). Administration of vitamin E (200 mg/kg) and oil (60 mg/kg) alone had no significant effects on the GSH content compared to the control group (Figure 2).

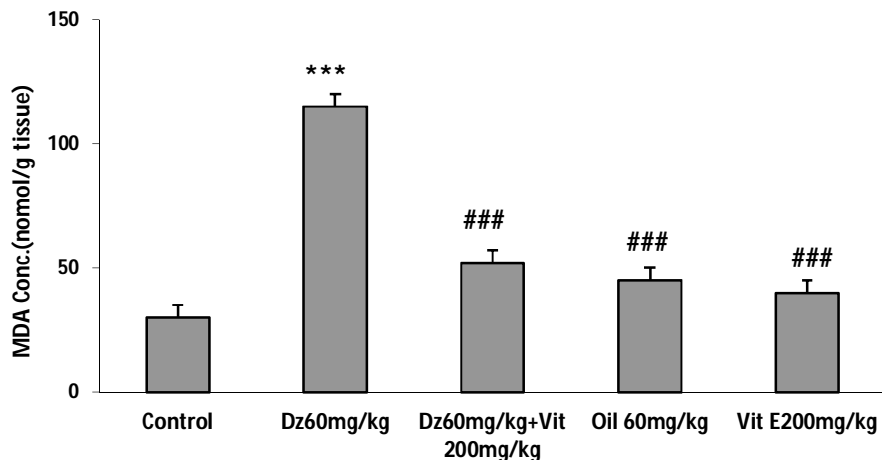


Figure 1. Effects of DZN and vit E on MDA levels in groups.

*** $P < 0.001$ vs. control, ### $P < 0.001$ vs DZN

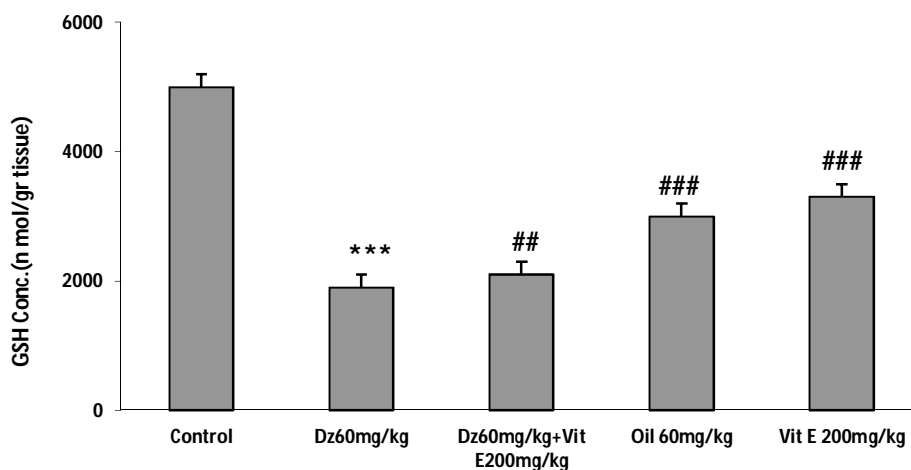


Figure 2. Effects of DZN and vit E on GSH levels in groups.

*** $P < 0.001$ vs. control, ### $P < 0.001$ vs DZN, ## $P < 0.01$ vs DZN

DISCUSSION

DZN is not only used in pest control of fruits and plants, but it is also used as an ectoparasiticide for cattle in veterinary applications [21]. DZN is absorbed from the gastrointestinal tract and rapidly metabolized [8]. Organophosphate insecticides induce biochemical and histopathological changes in several organs, such as liver, kidney, immune system, pancreas, and cardiac and vascular walls [22,23]. One of the targeted organs is the ovary, which has a major role in reproductive function by synthesizing hormones and producing oocyte [24, 9]. This study was done to investigate the effects of DZN, an organophosphate insecticide, on MDA and GSH levels and assess the protective role of vitamin E in rat ovarian tissues. One of the mechanisms of toxicity is increasing oxidative stress by the generation of free radicals and producing tissue lipid peroxidation. The intensity of lipid peroxidation was assessed through the measurement of MDA levels in ovarian tissues. The increased MDA content is a significant indicator of lipid peroxidation. This study showed that exposure to DZN (60 mg/kg) for two weeks significantly increased MDA level as compared with the control group ($P < 0.001$). Ogutcu *et al.* showed that DZN raises MDA level in heart tissues of rats, which is an indicator of free radical formation in this organ [7]. Koc *et al.* confirmed that endosulfan and malathion exposure increase MDA levels in ovarian tissues of female rats which is an indicator of free radicals formation and lipid peroxidation during metabolism of these insecticides [25,26]. Jahromi *et al.* found that malathion which is one of the organophosphate insecticides also may increase MDA level in ovary which is a definite reaction caused by released radicals from body and lipids metabolisms [4]. Previous studies have shown that DZN raised the lipid peroxidation level in erythrocytes and pancreas tissues of rats [7,13,27]. Several studies have also indicated that organophosphate insecticides increase MDA level in hepatic, cerebral, pulmonary, pancreatic, intestinal, and cardiac tissues and these changes are accompanied by increasing antioxidant system activities in some tissues [28,29].

In the present study, exposure to DZN (60 mg/kg) significantly decreased GSH content in ovary compared to the control group ($P < 0.001$).

Manna *et al.* reported that reduction of GSH content is an important indicator of oxidative damage in heart tissues [30]. Razavi *et al.* reported that exposure to DZN significantly increases MDA levels and decreases GSH contents in heart tissues [31]. The previous studies have also indicated that exposure to fenthion, an organophosphate insecticide, decreases GSH level and increases MDA level in erythrocytes of mice and rats [29,32]. Shah *et al.* reported that DZN administration induces lipid peroxidation in a dose-dependent manner in rats. He also demonstrated that DZN treatment decreases renal GSH, reduces the activities of antioxidant enzymes, including the enzymes involved in GSH metabolism and large production of oxidants which is associated with renal damage; all of which are involved in the cascade of events leading to DZN-mediated renal oxidative stress and toxicity [1]. Cells have several ways to reduce the effects of oxidative stress, through repairing damage (damaged nucleotides and lipid peroxidation created by products) or reducing oxidative damage by enzymatic and non-enzymatic antioxidants [7]. Vitamin E, a non-enzymatic antioxidant, is a lipid-soluble vitamin present in biological membrane [33,34]. Vitamin E allows free radicals to remove a hydrogen atom from the antioxidant molecule rather than from polyunsaturated fatty acids; thus, it breaks the chain of free radical reactions; the resulting radical is relatively inactive [35]. Minerals and vitamins are essential for the normal functioning of the reproductive system [36]. In the present study, vitamin E was administered via gavage for 14 days. The experimental group 2 received vitamin E plus DZN while experimental group 3 received vitamin E alone. Vitamin E (200 mg/kg) plus DZN significantly decreased the level of MDA compared to DZN treated rats ($P < 0.001$) and increased the GSH content compared to DZN treated rats ($P < 0.01$). Sutcu *et al.* have also shown that DZN increased lipid peroxidation in erythrocytes of rat and combinations of vitamin C and E reduce lipid peroxidation [37]. Yilmaz *et al.* reported that oxidative stress contributes to DZN-induced brain toxicity and vitamins E plus C combination may have a protective effect on this toxicity [38]. Kalender *et al.* observed that endosulfan administration increases MDA level in rats and

vitamin E protects cells and cellular structures from oxidative damage by reducing the MDA level [39]. A different study reported that vitamins C and E prevent hepatotoxicity induced by methyl parathion in rats [34]. Ogutcu *et al.* found that vitamin E reduces MDA level in DZN-induced heart tissue toxicity but does not prevent toxicity completely [7].

CONCLUSION

Based on the findings of this study, it can be concluded that DZN causes toxicity in ovarian tissues by inducing oxidative stress, reducing GSH content, and increasing MDA level. Vitamin E can protect ovarian tissues against this toxicity by reducing MDA level and increasing GSH content.

ACKNOWLEDGMENTS

The present study was part of MSc thesis in anatomical research. This study was conducted under contract NO. 911097 supported by a grant from the Research Council of Mashhad University of Medical Sciences. The authors wish to declare their gratitude to Research the Council of Mashhad University of Medical Science and Mrs. Motajadded and Mrs. Ziaee.

REFERENCES

1. Shah MD, Iqbal M. Diazinon-induced oxidative stress and renal dysfunction in rats. *Food and chemical toxicology*. 2010;48(12):3345-53.
2. Reece R, Handson P. Observations on the accidental poisoning of birds by organophosphate insecticides and other toxic substances. *The Veterinary Record*. 1982;111(20):453-5.
3. Yehia MA, El-Banna SG, Okab AB. Diazinon toxicity affects histophysiological and biochemical parameters in rabbits. *Experimental and Toxicologic Pathology*. 2007;59(3):215-25.
4. Jahromi VH, Koushkaki MNER, Kargar H. The Effects of Malathion Insecticide on Ovary in Female Rats. *National park forschung in der schweiz (Switzerland Research Park Journal)*. 2012;101(5):231-5.
5. Uzun FG, Kalender S, Durak D, Demir F, Kalender Y. Malathion-induced testicular toxicity in male rats and the protective effect of vitamins C and E. *Food and chemical toxicology*. 2009;47(8):1903-8.
6. Casas E, Bonilla E, Duclomb Y, Betancourt M. Differential effects of herbicides atrazine and fenoxprop-ethyl, and insecticides diazinon and

malathion, on viability and maturation of porcine oocytes in vitro. *Toxicology in vitro*. 2010;24(1):224-30.

7. Ogutcu A, Uzunhisarcikli M, Kalender S, Durak D, Bayrakdar F, Kalender Y. The effects of organophosphate insecticide diazinon on malondialdehyde levels and myocardial cells in rat heart tissue and protective role of vitamin E. *Pesticide biochemistry and physiology*. 2006;86(2):93-8.
8. Kalender S, Ogutcu A, Uzunhisarcikli M, Açikgoz F, Durak D, Ulusoy Y, et al. Diazinon-induced hepatotoxicity and protective effect of vitamin E on some biochemical indices and ultrastructural changes. *Toxicology*. 2005;211(3):197-206.
9. Güney M, Demirin H, Oral B, Özgüner M, Bayhan G, Altuntas I. Ovarian toxicity in rats caused by methidathion and ameliorating effect of vitamins E and C. *Human & experimental toxicology*. 2007;26(6):491-8.
10. ElMazoudy RH, Attia AA, AbdelGawad HS. Evaluation of developmental toxicity induced by anticholinesterase insecticide, diazinon in female rats. *Birth Defects Research Part B: Developmental and Reproductive Toxicology*. 2011;92(6):534-42.
11. Kalender Y, Uzunhisarcikli M, Ogutcu A, Acikgoz F, Kalender S. Effects of diazinon on pseudocholinesterase activity and haematological indices in rats: the protective role of vitamin E. *Environmental toxicology and pharmacology*. 2006;22(1):46-51.
12. Whyatt RM, Garfinkel R, Hoepner LA, Holmes D, Borjas M, Williams MK, et al. Within-and between-home variability in indoor-air insecticide levels during pregnancy among an inner-city cohort from New York City. *Environmental health perspectives*. 2007;383-9.
13. Altuntas I, Kilinc I, Orhan H, Demirel R, Koylu H, Delibas N. The effects of diazinon on lipid peroxidation and antioxidant enzymes in erythrocytes in vitro. *Human & experimental toxicology*. 2004;23(1):9-13.
14. Hariri AT, Moallem SA, Mahmoudi M, Memar B, Hosseinzadeh H. Sub-acute effects of diazinon on biochemical indices and specific biomarkers in rats: protective effects of crocin and safranal. *Food and chemical toxicology*. 2010;48(10):2803-8.
15. Agarwal A, Aponte-Mellado A, Premkumar BJ, Shaman A, Gupta S. The effects of oxidative stress on female reproduction: a review. *Reprod Biol Endocrinol*. 2012;10(1):49-50.
16. Possamai F, Fortunato J, Feier G, Agostinho F, Quevedo J, Wilhelm Filho D, et al. Oxidative stress after acute and sub-chronic malathion intoxication in Wistar rats. *Environmental*

- toxicology and pharmacology. 2007;23(2):198-204.
17. Esteghamati A, Zarban A, Doosti M. Evaluation of antioxidant status and oxidative stress markers in type II diabetes mellitus. *Iranian Journal of Endocrinology and Metabolism*. 2001;3(4):239-45.
 18. Salehi B, Vakilian K, Ranjbar A. Relationship of Schizophrenia with Lipid Peroxidation, Total Serum Antioxidant Capacity and Thiol Groups. *Iranian journal of psychiatry and clinical psychology*. 2008;14(2):140-5.
 19. Uchiyama M, Mihara M. Determination of malonaldehyde precursor in tissues by thiobarbituric acid test. *Analytical biochemistry*. 1978;86(1):271-8.
 20. Moron MS, Depierre JW, Mannervik B. Levels of glutathione, glutathione reductase and glutathione S-transferase activities in rat lung and liver. *Biochimica et Biophysica Acta (BBA)-General Subjects*. 1979;582(1):67-78.
 21. Garfitt S, Jones K, Mason H, Cocker J. Exposure to the organophosphate diazinon: data from a human volunteer study with oral and dermal doses. *Toxicology letters*. 2002;134(1):105-13.
 22. Yavuz T, Delibas N, Yildirim B, Altuntas I, Candir O, Cora A, et al. Vascular wall damage in rats induced by organophosphorus insecticide methidathion. *Toxicology letters*. 2005;155(1):59-64.
 23. Gomes J, Dawodu A, Lloyd O, Revitt D, Anilal S. Hepatic injury and disturbed amino acid metabolism in mice following prolonged exposure to organophosphorus pesticides. *Human & experimental toxicology*. 1999;18(1):33-7.
 24. Mattison DR, Thomford PJ. The mechanisms of action of reproductive toxicants. *Toxicologic pathology*. 1989;17(2):364-76.
 25. Koc N, Kayhan F, Sesal C, Muşlu M. Dose-dependent effects of endosulfan and malathion on adult Wistar albino rat ovaries. *Pakistan journal of biological sciences: PJBBS*. 2009;12(6):498-503.
 26. Fulia A, Chauhan P, Sharma R. Ameliorating effect of vitamin E on testicular toxicity induced by endosulphan in *Capra hircus* in vitro. *J Pharmacol Toxicol*. 2011;6:133-40.
 27. Gokalp O, Buyukvanli B, Cicek E, Ozer MK, Koyu A, Altuntas I, et al. The effects of diazinon on pancreatic damage and ameliorating role of vitamin E and vitamin C. *Pesticide biochemistry and physiology*. 2005;81(2):123-8.
 28. Buyukokuroglu ME, Cemek M, Yurumez Y, Yavuz Y, Aslan A. Antioxidative role of melatonin in organophosphate toxicity in rats. *Cell biology and toxicology*. 2008;24(2):151-8.
 29. Lukaszewicz-Hussain A. Role of oxidative stress in organophosphate insecticide toxicity—Short review. *Pesticide biochemistry and physiology*. 2010;98(2):145-50.
 30. Manna P, Sinha M, Sil PC. Amelioration of cadmium-induced cardiac impairment by taurine. *Chemico-biological interactions*. 2008;174(2):88-97.
 31. Razavi BM, Hosseinzadeh H, Movassaghi AR, Imenshahidi M, Abnous K. Protective effect of crocin on diazinon induced cardiotoxicity in rats in subchronic exposure. *Chemico-biological interactions*. 2013;203(3):547-55.
 32. Yurumez Y, Cemek M, Yavuz Y, Birdane YO, Buyukokuroglu ME. Beneficial effect of N-acetylcysteine against organophosphate toxicity in mice. *Biological and Pharmaceutical Bulletin*. 2007;30(3):490-4.
 33. Banudevi S, Sharmila M, Murugesan P, Srinivasan N, Balasubramanian K, Aruldas M, et al. Effects of Vitamin C and E on PCB (Aroclor 1254) induced oxidative stress, androgen binding protein and lactate in rat Sertoli cells. *Reproductive Toxicology*. 2004;19(2):201-8.
 34. Uzunhisarcikli M, Kalender Y. Protective effects of vitamins C and E against hepatotoxicity induced by methyl parathion in rats. *Ecotoxicology and environmental safety*. 2011;74(7):2112-8.
 35. Pascoe GA, Olafsdottir K, Reed DJ. Vitamin E protection against chemical-induced cell injury: I. Maintenance of cellular protein thiols as a cytoprotective mechanism. *Archives of biochemistry and biophysics*. 1987;256(1):150-8.
 36. Mohammadi S, Jalali M, RezaNikraves M, Sankian M, Gholamin M, Fazel A, et al. Combination of vitamin E with L-carnitine increase CatSper Genes expression in the aging mouse testis. *European Journal of Experimental Biology*. 2013;3(4):77-83.
 37. Sutcu R, Altuntas I, Buyukvanli B, Akturk O, Ozturk O, Koylu H, et al. The effects of diazinon on lipid peroxidation and antioxidant enzymes in rat erythrocytes: role of vitamins E and C. *Toxicology and industrial health*. 2007;23(1):13-7.
 38. Yilmaz N, Yilmaz M, Altuntas I. Diazinon-induced brain toxicity and protection by vitamins E plus C. *Toxicology and industrial health*. 2012;28(1):51-7.
 39. Kalender S, Kalender Y, Ogutcu A, Uzunhisarcikli M, Durak D, Açikgoz F. Endosulfan-induced cardiotoxicity and free radical metabolism in rats: the protective effect of vitamin E. *Toxicology*. 2004;202(3):227-35.