

Ingestion of Caustic Substances in Adults: A Review Article

Andon Chibishev^{1*}, Zanina Pereska¹, Vesna Chibisheva², Natasa Simonovska¹

Received: 22.06.2012

Accepted: 05.09.2012

ABSTRACT

Background: Ingestion of caustic agents can cause serious damages of the upper gastrointestinal tract and in some cases this kind of poisoning may have fatal outcomes.

Acute caustic intoxications are one of the main problems in the modern clinical toxicology since they mainly affect young people with psychic disorders, suicidal intent, and alcohol addiction.

Text: In diagnostic evaluation of this kind of poisoning, different procedures are used. Today's golden standard for determination of the grade and extent of the lesion is esophagogastroduodenoscopy (EGD) performed in the first 12-24 hours following corrosive ingestion.

In some patients, some late complications, such as esophageal stenosis and gastric stenosis, which are the most common, as well as carcinoma of the upper gastrointestinal tract, which is rarely seen, can be detected.

Acute caustic poisonings are treated with specific kinds of protocols. According to them, first, an attempt is made to neutralize the poison. Combinations of antibiotics, anti-secretory drugs, and collagen synthesis inhibitors are used. As a support therapy, nutritional liquids can be utilized, and in the most unmanageable cases, esophageal dilatation, stent placement and surgery are used.

Conclusion: In the future, caustic poisonings will remain a serious socio-medical issue, due to the difficult clinical presentation, expensive diagnostic protocol, extended hospitalization, and possible permanent disability.

Keywords: Caustic agents, Esophageal Lesions, Esophagogastroduodenoscopy, Post-Corrosive Injuries.

IJT 2013; 723-734

INTRODUCTION

According to the annual report of the American Association of Poison Controls, there are about 200,000 caustic intoxications annually, most commonly with acid and alkaline substances that are regularly used as cleansing agents in the households (1,2). In Republic of Macedonia, about 75-80 caustic intoxications are recorded per year. They are more often detected among women and in 95% of the cases they are with suicidal intent (3). Post-corrosive injuries with different degrees of severity can occur

along the entire esophagus particularly in the middle and distal part, more precise at the level of physiological narrowing. Also, they can appear in the gastric antrum and pylorus (4,5). Caustic poisonings are related to numerous complications which can cause fatal outcomes, most often seen during the acute phase of the intoxication.

Esophageal carcinoma may develop as a late complication, which its onset is observed 40-60 years after caustic ingestion (6-8).

Caustic poisonings occur after ingestion of caustic substances, such as acids (acetic, hydrochloric, sulfuric, lactic,

1- Clinical Center, University Clinic of Toxicology, Skopje, Republic of Macedonia.

2- Faculty of Medicine, Saints Cyril and Metodius University, Skopje, Republic of Macedonia.

*Corresponding author: E-mail: toksikourgentna@gmail.com

oxalic), alkalis (sodium and potassium agents, soaps, detergents), heavy metal salts, formalin, and many other chemical agents. Lye is a general term in the American literature, denoting strong alkali found in cleansing agents (9, 10).

The most commonly abused substance among acids is hydrochloric acid. It is often used in countries like India and Taiwan as opposed to the USA where its abuse is less than 5%. In Republic of Macedonia, this acid is easily accessible as a sanitary cleansing agent and it is used as an oral poison in more than 50% of the cases. Hydrochloric acid causes severe damages of the upper gastrointestinal tract, usually gastric stenosis (11). We have recorded some uncommon poisonings in which our patients abused agents such as cleaning products that contain sodium hypochlorite (NaClO). Atypical are also some serious injuries caused by acetic acid (CH₃COOH) usually used in preparation of food. It is often abused during autumn when people prepare conserved vegetables for winter. There are a small number of exceptional intoxications caused by ingestion of battery fluids (sulfuric acid), antirust compounds (oxalic acid), household bleaches and hydrogen peroxide (12). All these unusual poisonings rarely cause severe and serious injuries of the upper gastrointestinal tract.

Alkalis, such as sodium hydroxide (NaOH) and potassium hydroxide (KOH), are also being abused. They have high pH values and can be found in the market as components of soaps, detergents, cleaning tablets, and cosmetics. Their abuse is more frequent in the USA and member states of the European Union. As acids, they also cause severe post corrosive injuries of the upper gastrointestinal tract and late post corrosive complications. The most common complications are esophageal and gastric stenosis, which are found in greater percentages than in poisonings with acid substances (13, 14).

Pathophysiology of this kind of poisoning describes the cascade of

reactions which lead to tissue damage. Acids cause injuries due to coagulation necrosis, transformation of proteins, and hemoglobin. Alkalis cause transformation of tissue proteins into proteinates and fats into soaps which result in liquefaction necrosis (15).

Corrosive substances with a pH of less than 2 or greater than 12 are highly corrosive and can cause tissue necrosis. A concentrated solution of sodium hydroxide (22.5% and 30%) can cause perforation of the esophageal wall, mediastinitis, and fatal outcome within seconds (16).

Caustic agents can affect the entire gastrointestinal tract and the severity of the post corrosive lesions is determined by the nature of the caustic substance, pH value, quantity ingested, concentration of the solution, duration of exposure, and the act of swallowing. Also, different forms of caustic substances cause post corrosive injuries on different gastrointestinal areas. Ingestion of agents in solid or gel forms causes injuries of the oropharynx and proximal esophageal segment, while liquid substances cause injuries on the middle and distal segments of the esophagus and stomach (10).

Acute caustic intoxications cause a particular histological appearance of the esophageal and gastric walls where thrombosis of the small vessels can be predominantly seen.

The cells develop high temperature due to metabolic changes, and after a few days, they are overtaken by bacterial invasion (17). The healing process begins three weeks after ingestion with collagen deposition in the first week; later with development of granulation tissue and fibrosis, which leads to the incidence of esophageal and/or stomach strictures within the next 8 weeks to 8 months (18). Esophageal stenosis most frequently develops at the cricopharyngeal area, at the level of the aortic arch and tracheal bifurcation and the lower esophageal sphincter. Gastric stenosis mostly occurs in the atrium and pylorus.

Caustic substances cause three different degrees of post-corrosive injuries, where the third degree is characterized by perforation of the wall of the esophagus or stomach (19).

MAIN TEXT

Patients with acute caustic intoxications present a unique clinical state due to the injuries in the upper gastrointestinal tract. They have constant burning pain in the mouth, throat, and chest and severe pains in the stomach followed by nausea and vomiting. Symptoms usually appear right after caustic ingestion, rarely after a couple of hours and they last several days or weeks. Regular findings are ulcers or whitish plaques in the oral cavity, palatal mucosa, and pharynx which lead to edema, hypersalivation, and difficulty in swallowing (20). During the acute phase, the patients are in a very serious condition because they have developed laryngospasm with dyspnea, tachypnea, dysphonia, and aphonia. Among the most critical cases are those with endotracheal or bronchial necrosis with mediastinitis, due to substance aspiration, and they may often have fatal endings (21).

Lesions in the oral cavity are very painful and they often express contact

bleeding. Absence of extensive oropharyngeal injuries does not rule out severe injuries of the lower segments. In 10% to 30% of patients with severe esophageal post-corrosive burns, there are no local changes in the oropharynx. One survey showed the 37% presence of esophageal injuries (II and III degree) among patients that had not developed evident oropharyngeal damages (22- 23). By contrast, some reviews reported that 70% of patients with severe oropharyngeal injuries did not have noticeable esophageal damages. Therefore, injuries of the oropharynx are not a reliable indicator for the eventual burns located in the esophagus (23).

Perforation of the gastrointestinal wall may be the most serious complication in the acute phase and it requires immediate consultation with an abdominal surgeon. Generally, gastric perforation occurs and patients are immediately transferred for an emergency abdominal surgery.

Post-corrosive injuries usually appear in the first 48 hours or they may be delayed until the 14 days after caustic ingestion (24).

General condition of the patient can be complicated by a large liquid loss, metabolic acidosis, and renal failure.

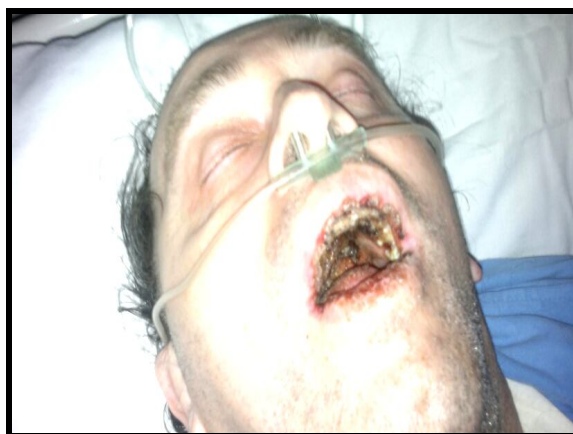


Figure 1. A patient with widespread oral post-corrosive lesions

In long-term management of patients with acute caustic intoxications, some difficulties related to the late complications exist. They happen very often and are usually quite extensive. Advanced diagnostics and modern approaches have reduced the percentage of post-corrosive late complications of the upper gastrointestinal tract. Nevertheless, they still present a major medical and social issue, both by their clinical presentation and therapeutic protocols. Also, post-corrosive late complications restrict the patients' everyday life.

The most common late complications are esophageal strictures and stenosis, gastric stenosis of the antrum and pylorus, and esophagus and stomach cancer (25, 26).

Patients with strictures and stenosis of the esophagus usually complain about difficult swallowing and also a feeling of

pressure behind the sternal bone. These symptoms indicate narrowing of the esophagus. They may appear three weeks after caustic ingestion, during the first three months or, according to some authors, even after one year following caustic ingestion (Figure 2). Stenosis is more commonly associated with ingestion of caustic poison in liquid form than in crystal form.

Onset of symptoms, like full stomach, nausea, vomiting, and extreme weight loss, suggest gastric obstruction, with development of stenosis of antrum or pylorus. It commonly happens in the first 5 to 6 weeks after intoxication and according to some authors even after several years, but yet rarely compared with esophageal stenosis (Figure 3). It is most frequently found after acid ingestion although many cases of gastric stenosis have been reported after alkaline ingestion.

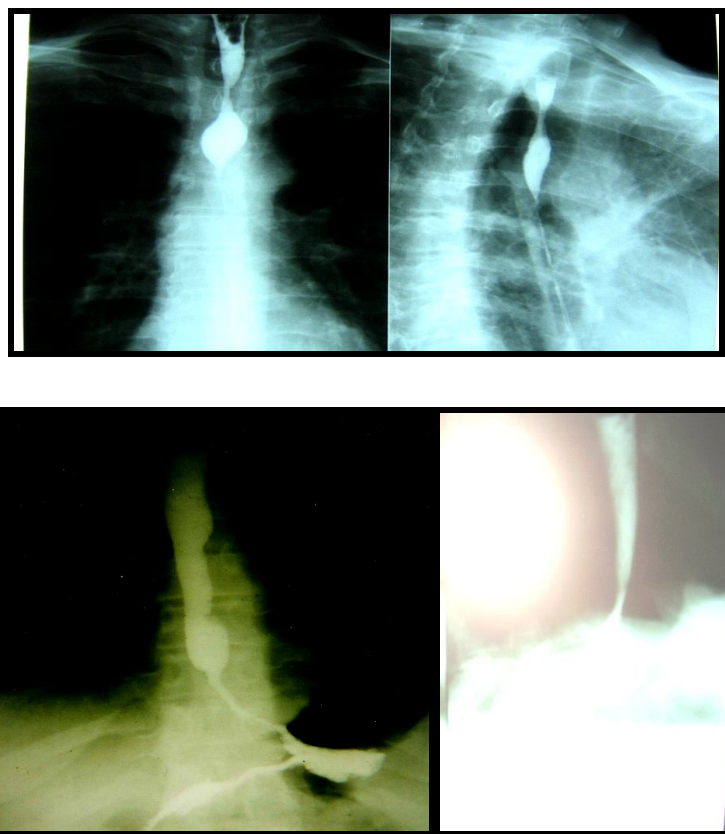


Figure 2. Late post-corrosive changes in the mid and low parts of the esophagus

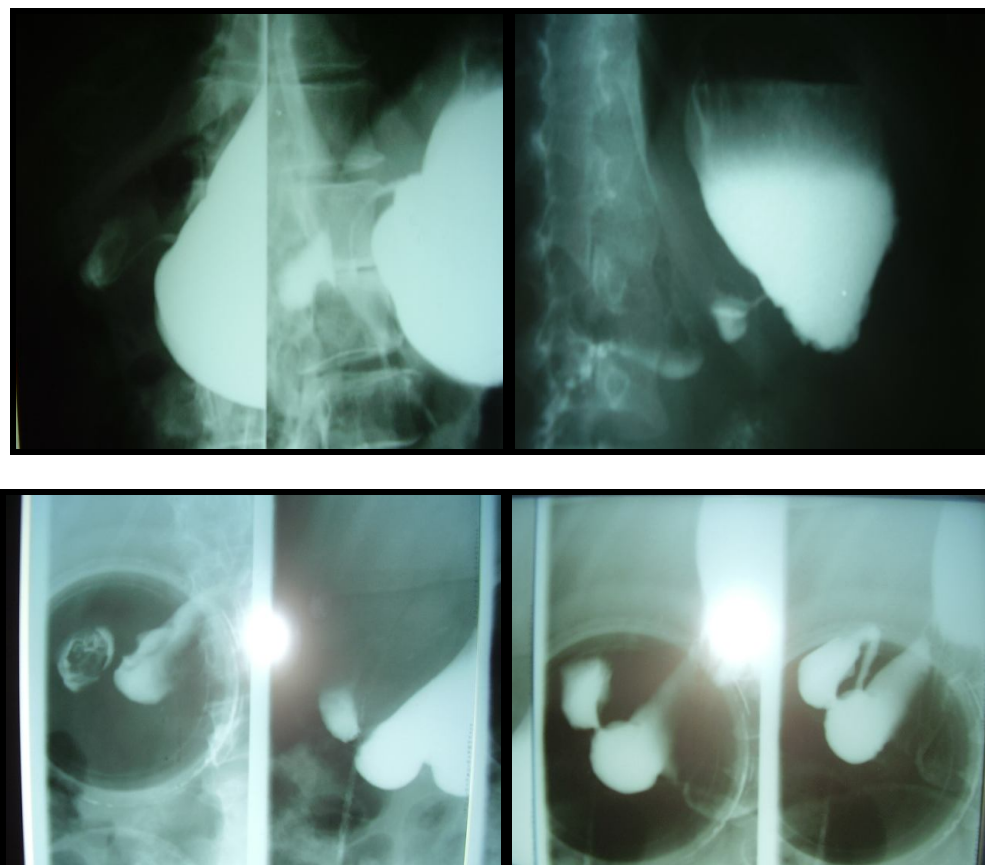


Figure 3. Late post-corrosive complications located in the antropyloric and pyloric gastric areas

Managing such intoxications may be very difficult, but still quite motivating. It must start right after admission to hospital. Earlier protocols suggested immediate use of milk and water during the acute phase, in the first couple of hours, but to date their advantage has not been proven in controlled studies. On the other hand, milk can cause some additional post-corrosive lesions due to the chemical reactions and further problems in performing an urgent esophagogastroduodenoscopy (27).

Patients should be rapidly sent to a radiological examination, starting with plain radiography of the chest and abdomen. These investigations can provide helpful information about the mediastinal processes and they can show us signs of esophageal or gastric perforation,

described as air in the mediastinum or under the diaphragm.

Esophagogastroduodenography with gastrographin performed 25-30 days after caustic ingestion may provide useful information about the changes in the esophageal and gastric lumen. Some authors prefer barium sulfate as less irritant, especially immediately after ingestion, for monitoring the development of complications, or when the urgent esophagogastroduodenoscopy is absolutely contraindicated. Nonetheless, this procedure is not suggested during the acute phase, especially in cases with suspicion of eventual perforation (28,29).

Esophagogastroduodenoscopy, on the other hand, is a very sophisticated and sovereign method for diagnostic evaluation of acute caustic intoxications and lesions

of the upper gastrointestinal tract. The most optimal time frame for urgent esophagogastroduodenoscopy is in the first 12-24 hours after ingestion of the caustic substance. This diagnostic procedure should be avoided between the 4th and the 14th days after ingestion because of intense inflammatory changes, vascular thrombosis and healing process of the post-corrosive lesions (11).

Unfortunately, there are still controversial opinions about the timing and method of performing this procedure. Some suggest that all patients with discrete symptoms of caustic ingestion have to be subjected to endoscopy. In patients with no symptoms and no signs of oropharyngeal injuries, endoscopy should not be performed, but they should still be admitted to hospital and set under an intensive monitoring during the first 48 hours after ingestion.

However, the fact that even 20% of post-corrosive poisonings pose no signs of oropharyngeal injury as well as the unproved correlation between the symptomatology and the severity of post-corrosive injuries advocate a legitimate need, with no exception, of upper

endoscopy in all poisonings with caustic substances (30).

Today's modern approach recommends performing urgent esophagogastroduodenoscopy after previous sedation, general anesthesia, and endotracheal intubation. During the procedure, several complications might be faced, among which the iatrogenic perforation is the most severe, but luckily very rare. Introduction of flexible endoscopic tubes has made this invasive method quite safer.

Esophagogastroduodenoscopy gives us useful data on the existence of post-corrosive injuries and if they are documented, an adequate treatment has to be initiated as soon as possible (31).

Endoscopic classification of post-corrosive injuries in the upper gastrointestinal tract is of paramount importance in diagnosis and treatment of acute corrosive intoxications. Kikendall (32) suggested a classification in four grades (Table 1).

Besides this classification, some authors use the classification made by Zargar (33) (Table 2).

Table 1. Kikendall's classification

GRADE I:	edema and erythema of the mucosa
GRADE II A:	hemorrhage, erosions, blisters, superficial ulcers
GRADE III B :	circumferential lesions
GRADE III:	deep grey or brownish-black ulcers
GRADE IV:	perforation

Table 2. Zargar's classification

GRADE 0:	normal mucosa
GRADE I:	edema and erythema of the mucosa
GRADE II A:	hemorrhage, erosions, blisters, superficial ulcers
GRADE II B:	circumferential lesions
GRADE III A:	focal deep grey or brownish-black ulcers
GRADE III B:	extensive deep grey or brownish-black ulcers
GRADE IV:	perforation

Endoscopic ultrasound and computerized tomography are useful procedures in diagnosis that can more precisely determine the depth of the corrosive injuries.

The aim of therapy is to prevent perforation and to avoid progressive fibrosis and stenosis of the esophagus and stomach.

First line of treatment includes the emergency surgical interventions that are indicated in cases of esophageal or gastric perforation. They are really difficult to predict and can be treated only surgically. Patients with shock, coagulation disorders or acidosis and those who have ingested a large quantity of corrosive substances tend to develop severe post-corrosive injuries and laparotomy and resection of damaged segments may be beneficial in their treatment. Modern surgical approaches suggest placing of gastrostoma or jejunostoma for artificial nutrition.

In one of his studies, Zargar (33) suggests prompt surgical intervention in patients with severe post-corrosive injuries (grade IIIB) for decreasing mortality and morbidity in these patients. Some scholars are strongly in opposition to this method of treatment because they find determining the grade of post-corrosive lesions really difficult (34,35).

In some protocols, neutralization of caustic substances can be viewed as one of the first steps for treating caustic intoxications. In order to be effective, neutralization should be used within the first hour after ingestion of caustic poison. However, many other researchers state that this procedure is contraindicated because it produces additional heat in the tissues and increases the risk of further new lesions. Generally, alkalis can be neutralized with lemon or orange juice and mild vinegar, and acids with milk, eggs or antacids. Emetics are contraindicated because of re-exposition to the corrosive substance leading to the exacerbation of the injury. Activated charcoal is also contraindicated (36).

Antibiotics are often employed in treatment of acute caustic intoxications but their regular use and benefits of their use are still controversial. Since there is not a sufficient number of controlled studies that would confirm the need for using antibiotics, many authors do not recommend them. Some investigations on animal models have shown that post-corrosively injured mucosa is always attacked by bacteria that causes severe inflammation of the tissue followed by granulation and fibrosis. This is the main reason why antibiotics should be used in patients with acute caustic poisonings, especially broad spectrum antibiotics like those from penicillin family (37).

Another category of drugs used in treatment of these kinds of poisonings are corticosteroids but their use is also questionable. One big survey involved 361 cases and reported 19% of esophageal and stomach stenosis in patients who received corticosteroids and 41% of stenosis in those who were not treated with corticotherapy. Individuals included in this study received either dexamethasone (1 mg/kg/day) or prednisolone (2 mg/kg/day) (23).

Several other studies showed increased risk of complications, such as peritonitis and mediastinitis, in group of patients who were under corticotherapy and there was no relationship between its use and reduced occurrence of stenosis. A similar multicentric study comprising 572 patients conducted at the same time in several European countries indicated that corticosteroids have no significant influences on prevention of post-corrosive stenosis in acute corrosive poisonings (37).

Post-corrosive extensive injuries of the upper gastrointestinal tract hinder physiological nutrition in these patients and they become candidates for artificial nutrition. Very soon these patients suddenly fall into a severe general condition due to hypercatabolic state and negative alkali balance (5). Several modern types of artificial nutrition can be used and

the most appropriate one should be chosen according to the degree of esophageal and gastric damages revealed via urgent endoscopy.

In patients with grade I and grade II A of damages, total parenteral nutrition (TPI) in the first 24-48 hours, followed by liquid diet until the 10th day should be used. Afterwards, food intake can be in a more liberal regimen.

In patients with grades II B and III damage, the so-called "esophageal rest" is recommended. This means that patient must not take any food per os (nill per os-NPO). During the NPO period, the patient receives nutritional liquids given through nasogastric and nasoenteral tubes, gastrostoma or jejunostoma. Despite enteral nutrition, the patients can also be fed parenterally by peripheral and central

veins. Esophageal rest is explained with the fact that food particles enter the granulocytes of the esophageal wall and worsen the inflammation (16). Esophageal rest may last until the 10th day after corrosive ingestion or, according to some authors, until the 15th day or the first endoscopic control.

Intensive hyperalimentation and esophageal rest may decrease the number of late post-corrosive complications (stenosis and strictures), although this state has not been clearly described and confirmed in controlled studies (38,39).

If the patient can swallow his/her own saliva, several scholars recommend taking liquids (nutritional solutions, milk) 48 hours after caustic ingestion. (Figure 4, 5)

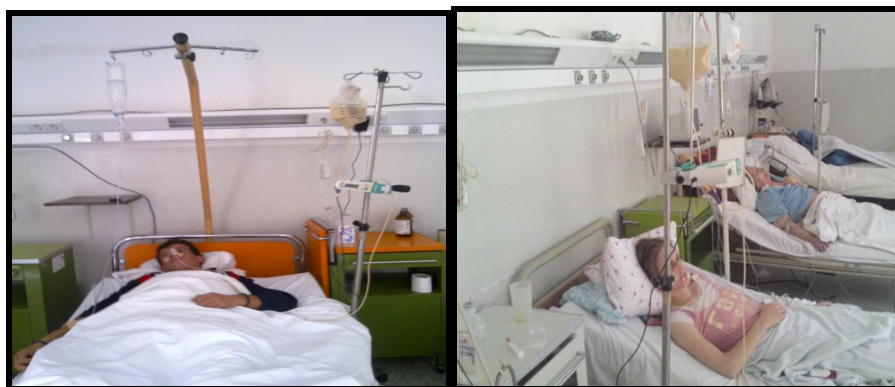

Figure 4. The patients with a nasojejunum tubes, who were fed enterally by enteroport pump system

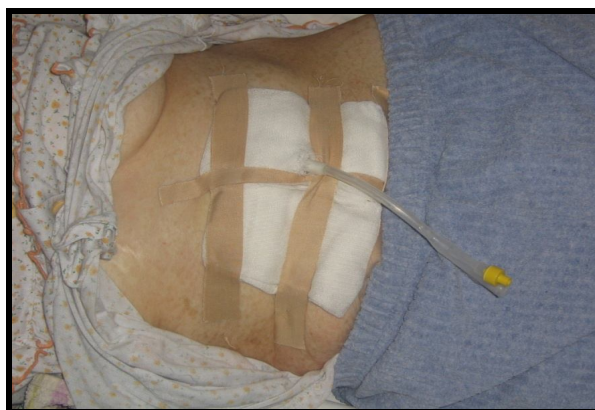

Figure 5. A patient with gastro-jejunal stoma

In some patients, retrograde intraluminal esophageal dilation can be performed for prevention or dilation of the already created esophageal narrowing. This procedure can be done immediately after intoxication or 15 days later. It is safest to start the esophageal dilatation 6 weeks after ingestion. Then it is performed every 2 to 3 months in several consecutive time intervals (40).

In spite of the presented positive experiences, this method is not recommended by many authors because it can traumatize the esophagus, cause bleeding and esophageal perforation, and increase predisposition to fibrosis formation (Figure 6).

Some studies also show the benefit of using sucralfate in treatment of caustic poisonings. They have shown its role in reducing the percentage of post-corrosive stenosis in the upper gastrointestinal tract (41).

In patients with IIB and III grades of esophageal injuries, a specially designed intraluminal stent can be placed under endoscopic control preventively or after the onset of stenosis. The limited number

of controlled studies has not given substantial support to this method (42).

At last, surgical intervention is indicated in cases with complete stenosis that cannot be treated with usual conservative methods; esophageal or gastric defects noticed on plain radiography; and when patients develop some kind of fistula. During surgical intervention, jejunum and colon are the most commonly used organs for esophageal replacement. Esophagectomy with colon interposition is the most frequently applied method in serious esophageal lesions (43). Gastric transposition is more recommended for children although there are data on high mortality rate (5%), anastomotic leakage (12%), and postoperative dilation due to onset of strictures (20%) (44).

Predictions in acute caustic poisonings are very alterable and they depend on the degree of esophageal and gastric lesions as well as the general health condition of the patient. The highest mortality rate has been recorded as a result of perforation and mediastinitis.

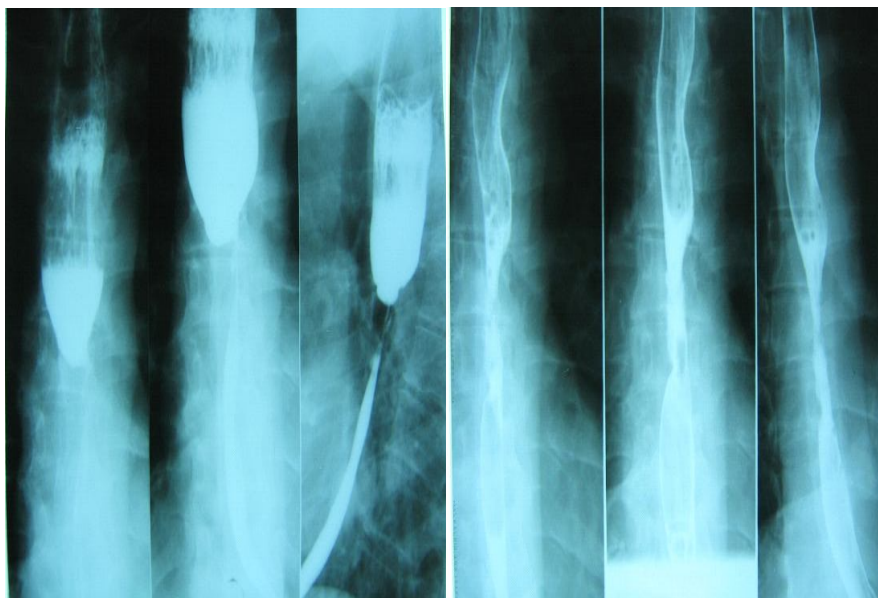


Figure 6. X-ray findings of narrowed mid- and distal esophagus and dilated proximal esophagus and X-ray findings of esophagus after retrograde intraluminal dilation

CONCLUSION

Acute caustic poisonings are a serious socio-medical issue, both from the sense of clinical presentation and the therapeutic approach. These poisonings cause severe chemical damages of the upper gastrointestinal tract, most commonly localized to the esophagus and stomach, presented with serious clinical signs and symptoms. Clinical examinations are hard to perform; hence, the treatment and outcome are often uncertain.

They are most commonly detected among young people in their most productive and active period of life. At the same time, they present a significant economic burden on the community due to expensive diagnostic and therapeutic programs and extended hospitalization.

Treatment of such intoxications requires modern medical approaches because of the severe clinical presentation in the acute phase and the need for extended evaluation, severe post-corrosive complications, and possibility of a life-time disability.

In the next five years, it would be necessary to study the problem with more controlled clinical surveys, which will look for new ways of reducing the high percentage of post-corrosive stenosis of the upper gastrointestinal tract and development of more efficient treatment protocols.

REFERENCES

- Bronstein AC, Spyker DA, Cantilena Jr LR, Green J, Rumack BH, Heard SE. 2006 annual report of the American Association of Poison Control Centers' National Poison Data System (NPDS). *Clinical Toxicology*. 2007;45(8):815-917.
- Litovitz TL, Klein-Schwartz W, White S, Cobaugh DJ, Youniss J, Omslaer JC, et al. 2000 Annual report of the American Association of Poison Control Centers Toxic Exposure Surveillance System. *American Journal of Emergency Medicine*. 2001;19(5):337-95.
- Chibishev A, Simonovska N, Shikole A. Post-corrosive injuries of upper gastrointestinal tract. *Contributions*. 2010;31(1):297-316.
- Bremholm L, Winkel R, Born P, Suku M. Acute esophageal necrosis. *Ugeskrift for laeger*. 2009;171(45):3282-3.
- Zwischenberger JB. Clare Savage, Akhil Bidan. Surgical Aspects of Esophageal Disease. *Am J Respir Crit Care Med*. 2002; 8: 1037-40
- Bozinovska C. Xenotic changes in acute corrosive intoxications. *Archives of Toxicology, Kinetics and Xenobiotic Metabolism*. 1998;3:115-7.
- Kochhar R, Sethy PK, Kochhar S, Nagi B, Gupta NM. Corrosive induced carcinoma of esophagus: report of three patients and review of literature. *Journal of gastroenterology and hepatology*. 2006;21(4):777-80.
- Alinejad A. Caustic injury to the upper gastrointestinal tract. . *Shiraz e medical journal*. 2003;4(1). Available from: http://www.sinatrc.ac.ir/_databank/_stdb/MAINview.asp?x_search=&No=1&key1=1208.
- Ramasamy K, Gumaste VV. Corrosive ingestion in adults. *Journal of clinical gastroenterology*. 2003;37(2):119-24.
- Kardon E. Caustic ingestion. *Emergency Medicine Toxicology*. Available from: <http://www.medicine.medscape.com>.
- Poley JW, Steyerberg EW, Kuipers EJ, Dees J, Hartmans R, Tilanus HW, et al. Ingestion of acid and alkaline agents: outcome and prognostic value of early upper endoscopy. *Gastrointest Endosc* 2004;60(3):372-7.
- Cibisev A, Nikolova-Todorova Z, Bozinovska C, Petrovski D, Spasovski G. Epidemiology of severe poisonings caused by ingestion of caustic substances. *Prilozi*. 2007;28(2):171-83.
- Triadafilopoulos G. Caustic esophageal injury in adults. Available from: <http://www.uptodate.com/contents/caustic-esophageal-injury-in-adults>.
- Katzka DA. Caustic injury to the esophagus. Current treatment options in gastroenterology. 2001;4(1):59-66.
- Christesen H. Ingestion of caustic agents. Epidemiology, pathogenesis, course,

- complications and prognosis]. *Ugeskrift for laeger*. 1993;155(31):2379-82.
16. Schild JA. Caustic ingestion in adult patients. *Laryngoscope*. 1985; 95(10):1199-201
 17. Zargar SA, Kochhar R, Nagi B, Mehta S, Mehta SK. Ingestion of corrosive acids. Spectrum of injury to upper gastrointestinal tract and natural history. *Gastroenterology*. 1989;97(3):702-7.
 18. Martins O Thomas, Ezekiel Ogunleye, Oladapo Somefun. Chemical injuries of the oesophagus: aetiopathological issues in Nigeria. *J Cardiothorac Surg*. 2009;4:56.
 19. Christesen H. [Diagnosis and treatment of caustic ingestion]. *Ugeskrift for laeger*. 1994;156(28):4125-6.
 20. Satar S, Topal M, Kozaci N. Ingestion of caustic substances by adults. *American journal of therapeutics*. 2004;11(4):258-61.
 21. Arévalo-Silva C, Eliashar R, Wohlgeleenter J, Elidan J, Gross M. Ingestion of caustic substances: a 15-year experience. *The Laryngoscope*. 2006;116(8):1422-6.
 22. Rakhmetov NR, Zhetimkarimov DS, Khrebtov VA, Aïmagambetov MZh, Bylegenov TA. [Surgical treatment of combined burn strictures of the esophagus and the stomach]. *Khirurgiia (Mosk)*. 2003;11:17-9.
 23. Korolev MP, Fedotov LE, Makarova OL. [Treatment of patients with combined burn strictures of the esophagus and stomach]. *Vestn Khir Im I I Grek*. 2005;164(2):70-2.
 24. Mamede R, De Mello Filho F. Treatment of caustic ingestion: an analysis of 239 cases. *Diseases of the Esophagus*. 2002;15(3):210-3.
 25. Atiq M, Kibria RE, Dang S, Patel DH, Ali SA, Beck G, et al. Corrosive injury to the GI tract in adults: a practical approach. *Expert Review of Gastroenterology and Hepatology*. 2009;3(6):701-9.
 26. Berthet B, Bernardini D, Lonjon T, Assadourian R, Gauthier A. Treatment of caustic stenoses of the upper digestive tract]. *Journal de chirurgie*. 1995;132(11):447-50.
 27. Fridtjof H, Knut H, Mari B, Anne N, Jose F, Oivind E, et al. Pre-hospital treatment of acute poisonings in Oslo. *BMC Emergency Medicine*. 2008;8:15.
 28. Sarfati E, Gossot D, Assens P, Celerier M. Management of caustic ingestion in adults. *British journal of surgery*. 1987;74(2):146-8.
 29. Chibishev A, Chibisheva B, Bozinovska C, Naumovski J. Oesophageal and gastric stenoses are common complications after acute oral poisoning with corrosive agents. *Maced J Med*. 2005;51(1-2):139-46.
 30. Hao-Tsai C, Chi-Liang C, Cheng-Hui L, Jui-Hsiang T, Yin-Yi C, Nai-Jen L, et al. Caustic ingestion in adults: The role of endoscopic classification in predicting outcome. *BMC Gastroenterology*. 2008; 8: 1-7.
 31. Munoz-Bongrand N, Gornet JM, Sarfati E. [Diagnostic and therapeutic management of digestive caustic burns]. *J Chir (Paris)*. 2002;139(2):72-6.
 32. Kikendall J. Caustic ingestion injuries. *Gastroenterology Clinics of North America*. 1991;20(4):847-57.
 33. Zargar SA, Kuchhar R, Mehta S, Kumar Mehta S. The role of fiberoptic endoscopy in the management of corrosive ingestion and modified endoscopic classification of burns. *Gastrointestinal endoscopy*. 1991;37(2):165-9.
 34. . Dzhafarov CM, Dzhafarov EC. Surgical treatment of cicatricial stricture of the esophagus and stomach after chemical burn. *Khirurgiia*. 2007(1):25-8.
 35. Abakumov M, Pinchuk T. Is antisecretory therapy of patients with chemical burn of the esophagus mandatory?. *Khirurgiia*. 2007(1):20-4.
 36. Peter M, Loeb-Abram M, Eisenstein. Caustic injury to the upper gastrointestinal tract. In :Sleisenger and fordtran's gastroinestinal and liver disease. 6th edition. WB Saunders company . 1998; 335-42.
 37. Pelclova D, Navratil T. Do corticosteroids prevent oesophageal stricture after corrosive ingestion? *Toxicological reviews*. 2005;24(2):125-9.
 38. Muñoz Botero NA, Pérez Cano AM, Rodríguez Herrera R, Rojas Gómez MP, Soler Páez FA. Nutrition therapy for adult patients with caustic injuries to gastrointestinal tract. *Nutr Hosp*. 2010 ;25:231-7.
 39. Chibisev A. Post-corrosive Late Complications in Esophagus and

- Stomach–Role of the Esophageal Rest. Med Arh. 2010;64:320-3.
40. Kochhar R, Kochhar S. Endoscopic balloon dilation for benign gastric outlet obstruction in adults. World Journal of Gastrointestinal Endoscopy. 2010;2(1):29-35.
 41. Temir ZG, Karkiner A, Karaca İ, Ortaç R, Özdamar A. The effectiveness of sucralfate against stricture formation in experimental corrosive esophageal burns. Surgery today. 2005;35(8):617-22.
 42. Brankov O. Severe combined corrosions of the esophagus and stomach-[diagnostic and treatment]. Khirurgiia. 2003;59(5):7-10.
 43. Chirica M, de Chaisemartin C, Goasguen N, Munoz-Bongrand N, Zohar S, Cattan P, et al. Colopharyngoplasty for the treatment of severe pharyngoesophageal caustic injuries: an audit of 58 patients. Annals of surgery. 2007;246(5):721-7.
 44. Cattan P, Munoz-Bongrand N, Berney T, Halimi B, Sarfati E, Celerier M. Extensive abdominal surgery after caustic ingestion. Annals of surgery. 2000;231(4):519-23.