

# Inhibition of Nephrotoxic Activity of *Mesobuthus Eupeus* Scorpion Venom by Commercial Polyvalent Antivenom in Rabbits

Ehsan Zayerzadeh<sup>\*1</sup>

Received: 12.07.2014

Accepted: 11.08.2014

## ABSTRACT

**Background:** Immunotherapy is the only specific treatment for scorpion envenomation. In the present study, the protective effects of polyvalent antivenom against histopathological complications in kidneys and marker changes (BUN and creatinine) induced by *Mesobuthus eupeus* (*Me*) scorpion venom was investigated in anesthetized rabbits.

**Methods:** Twenty four rabbits were randomized into four groups: six rabbits in control group were received 1 ml distilled water subcutaneously (group 1). In group 2, sublethal dose of *Me* venom (4 mg/kg) was injected subcutaneously. Simultaneously venom (subcutaneously 1ml of an distilled water solution containing 4 mg/kg of *Me* venom) and antivenom (intravenously 5 ml) were administered in six rabbits as group 3 animals. In group 4, rabbits received five ml of antivenom, 60 min after *Me* venom injection.

**Results:** In group 2, venom injection caused histopathological damages such as glomerular congestion, dilated vessels of interstitium and focal interstitial congestion in the kidney. It also increased creatinine and BUN levels 3 h after envenomation. Simultaneous administration of antivenom and venom prevented histopathological damage and marker changes. In group four, Immunotherapy decreased histopathological damages and prevented creatinine and BUN elevation at 3 h.

**Conclusion:** Polyvalent antivenom administration can prevent and neutralize nephrotoxic effects of *Mesobuthus eupeus* scorpion envenomation, if used at optimum conditions.

**Keywords:** Acute Kidney Injury, Antivenins, Creatinine, *Mesobuthus eupeus* Scorpion Venom.

IJT 2015; 1216-1221

## INTRODUCTION

Scorpionism is a known problem of medical and social importance in tropical and subtropical countries [1, 2]. *Mesobuthus eupeus* one of the major scorpions in Iran and its sting causes major public health problems. The majority of stings that occur in Iran are attributed to Buthidae family, which includes *Mesobuthus eupeus*, *Androctonus crassicauda*, *Odontobuthus odonturus* and *Apistobuthus pertigus*[3]. In addition, *Mesobuthus eupeus* shows high geographic distribution in Turkey, Iraq, Turkistan, Afghanistan and Pakistan. Therefore, *Mesobuthus eupeus* is known as a central Asian scorpion [4]. Radmanesh

demonstrated that 45% of all cases of scorpion stings in Iran were due to *Mesobuthus eupeus*[3]. There are some reports of acute renal failure following stinging of scorpions of Buthidae and scorpionidae family [5- 9]. Antivenom immunotherapy is the singular specific treatment for scorpion envenomin. Unfortunately, administration of antivenoms remains empirical and their efficacy is controversial, although some studies have described beneficial therapeutic effects [10-12]. On the other hand, some investigations demonstrated that scorpion antivenoms are not beneficial [13-15]. To the best of our knowledge, despite widespread use of polyvalent antivenom (PAV) for the treatment of

1. Department of Biology, Food Industry and Agriculture Research Center, Standard Research Institute, Karaj, Iran.

\*Corresponding Author: E-mail: zayerzadeh@standard.ac.ir

victims in Iran, no report has been published regarding its protective effects against histopathological complications in kidneys and renal failure induced by *Mesobuthus eupeus* scorpion venom. Therefore, this study was aimed to investigate protective effects of polyvalent antivenom in anesthetized rabbits following *Mesobuthus eupeus* envenomation.

## MATERIALS AND METHODS

### *Venom and Antivenom*

*Mesobuthus eupeus* venom was obtained by electric shock at the telson of scorpions collected from the same area of country in the department of Venomous Animals and Antivenom Production, Razi Vaccine and Serum Research Institute of Iran. The venom was lyophilized and stored at 4 °C until needed. The polyvalent antivenom was supplied as ampoules from Razi Vaccine and Serum Research Institute of Iran.

### *Experimental Protocol*

Twenty four male Newzeland white rabbits with an average weight of 2 kg were used in this study. All animals were housed under conditions of controlled light (12h light, 12h dark), temperature (24±1°C) and humidity (55±5%), with standard chow diet and water available *ad libitum*. All animals were anesthetized by intramuscular injection of 50 mg/kg ketamin and 5 mg/kg xylazine. Our protocol was in compliance with the recommendations of Animal Care Committee of Tehran University based on the 'Guide for Care and Use of Laboratory Animals'(NIH US publication 86-23, revised 1985). Group one animals (control group) were subcutaneously injected with 1 ml distilled water. Group 2 animals received sublethal dose (4 mg/kg) of *Me* venom subcutaneously. Venom (subcutaneously 1ml of a distilled water solution containing 4 mg/kg of *Me* venom) and antivenom (intravenously 5 ml) were administered simultaneously in six rabbits that were considered as group 3 animals. Finally, in group four, 5 ml of antivenom was injected 60 min after *Me* venom injection.

### *Histopathological Analyses*

After animals were euthanized, the kidneys were removed carefully and were immersed in 10% buffered formalin at room temperature and then sectioned transversely into 3-4 µm slices. Specimens were dehydrated in graded series of alcohol and xylene and embedded in paraffin. Multiple slices were made and stained by hematoxylin and eosin. Sections were viewed and photographed using a Nikon E200® light microscope (Japan).

### *Biochemical Analyses*

Blood samples were collected prior to the experiment and at 0, 1, 3 hours after treatments by cephalic vein puncture, in tubes without anticoagulant, to collect serum. Blood urea nitrogen (BUN) and creatinine were assayed in the sera using the photometry technology (COBAS INTEGRA® 400 plus system) and creatinine kit (Roche, Germany) according to the manufacturer's instructions. The enzyme values were expressed in international units (U/L).

### *Statistical Analyses*

All results were expressed as mean ± SEM. The statistical significance of differences among groups was analyzed by Student's *t*-test. Data were considered statistically significant if *p*-values were < 0.05.

## RESULTS

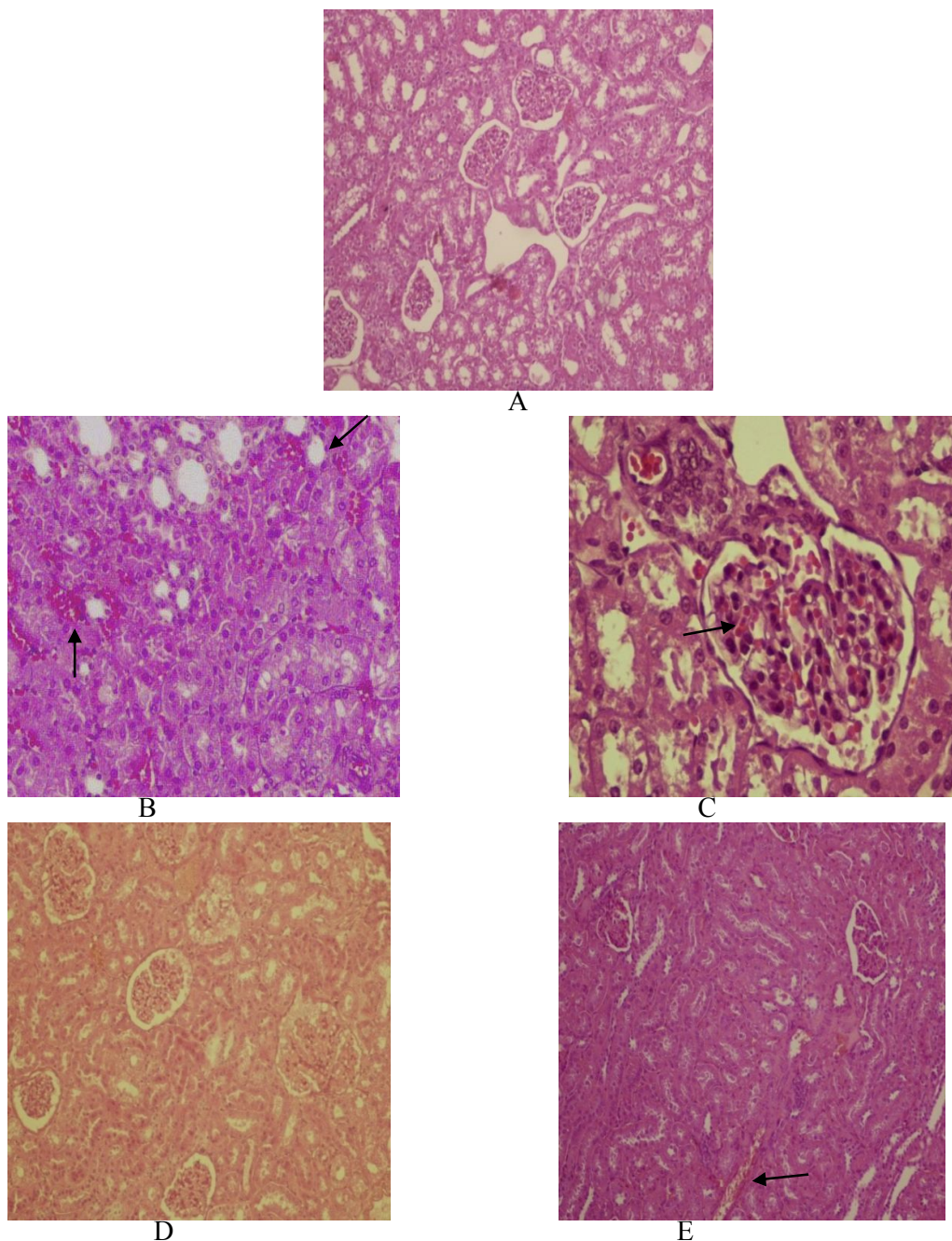
### *Histopathological Analyses*

Histopathological evaluation of the kidney tissues in animal treated by *Mesobuthus eupeus* venom (group 2) demonstrated glomerular congestion characterized by presence of erythrocytes in the glomerules and interstitial space, dilated vessels of interstitium and focal interstitial congestion (figure 1B, C). Immunotherapy in group 3 clearly prevented histopathological damage (figure 1D). Immunotherapy in group four decreased histopathological complications and we observed mild congestion in the glomerules and interstitial space and mild dilation in interstitial vessels (figure 1 E).

### Metabolic Changes

Significant elevation of creatinine and BUN was observed at 3 h after *Me* venom injection in group 2 (Table 1). In group 3, immunotherapy prevented marker changes and

creatinine and BUN levels remained normal at different time intervals (Table 2). In group 4, immunotherapy also prevented creatinine and BUN elevation at 3 h after treatment (in comparison with group 2) (Table 3).



**Figure 1.** Histopathological changes of kidney tissue induced by *Mesobuthus eupeus* venom and after immunotherapy. (A) control group (B, C) *Mesobuthus eupeus* venom treated group (D) antivenom administration simultaneous with *Mesobuthus eupeus* venom injection (E) antivenom administration 1 h after *Mesobuthus eupeus* venom injection. (A) normal kidney, (B) congested vessels in portal areas and dilated sinusoids (10x), (C) glomerular congestion (40x). (D) normal kidney, (E) mild glomerular congestion in kidney were present.

**Table 1.** Creatinine and BUN (mg/dl) serum levels in rabbits after 4 mg/kg *M.* evenom injection in different time intervals.

	Mean ± SEM					
	Creatinine(mg/dL)			BUN(mg/dL)		
	control	envenomed	P value	control	envenomed	P value
0	0.87 ± 0.23	0.81 ± 0.27	NS	24.3 ± 6.1	23.2 ± 8.3	NS
1	1.02 ± 0.34	1.1 ± 0.32	NS	23.7 ± 3.3	22.5 ± 7.2	NS
3	1.07 ± 0.2	2.72 ± 0.39	S	25.4 ± 4.6	48.6 ± 7.8	S

Mean values (standard error) are shown for the six animals in each group. NS: Not significant, S: significant

**Table 2.** Antivenom administration simultaneous with *Me* venom injection.

	Mean ± SEM				
	control	After 1h	p-value	After 3h	p-value
Creatinine(mg/dL)	0.87 ± 0.23	0.9 ± 0.44	ns*	0.85 ± 0.55	ns**
BUN(mg/dL)	24.3 ± 6.1	28.4 ± 9.3	ns*	25.4 ± 6.1	ns**

\*non-significant different from control at  $p < 0.05$  \*\* non-significant different from after 1 hour at  $p < 0.05$

**Table 3.** Antivenom administration 60 min after *Me* venom injection.

	Mean ± SEM				
	control	After 1h	p-value	After 3h	p-value
Creatinine(mg/dL)	0.87 ± 0.23	0.82 ± 0.35	ns	1.02 ± 0.29	ns
BUN(mg/dL)	24.3 ± 4.1	22.7 ± 5.8	ns	25.7 ± 5.2	ns

\*non-significant different from control at  $p < 0.05$  \*\* non-significant different from after 1 hour at  $p < 0.05$

## DISCUSSION

Severe histopathological damage and death due to scorpion stings is a common health problem in tropical and subtropical countries. However, 50 of the 1500 scorpion species that distributed in the world have proven deadly to humans and most of them belong to Buthidae family [16]. *Mesobuthus eupeus*'s sting can result in serious complications in major organs. Immunotherapy is the only specific treatment for scorpion sting but to our knowledge, this is the first investigation to evaluate neutralization potency of commercial polyvalent F(ab')<sub>2</sub> antivenom in Iran against nephrotoxic complications induced by *Me* venom in rabbits. In this study, injection of *Mesobuthus eupeus* scorpion venom in rabbits caused histopathological complications such as glomerular congestion, dilated interstitial vessels and focal interstitial congestion in kidneys of all animals. Pharmacokinetic studies in rats have previously shown that scorpion venom spreads rapidly from blood to tissues, and especially the kidneys, reaching a maximum concentration

around 15 min after inoculation [6, 17, 18]. Martins et al have demonstrated that snake *Crotalus durissus cascavella* venom induced proximal tubular damage in perfused isolated kidneys within two hours [19]. With respect to creatinine and BUN levels (table 1), significant statistical differences ( $p < 0.05$ ) between renal lesions were observed between groups at 1 and 3 h. Creatinine and BUN are the final products of protein metabolism and their levels increase in renal failure. There are some reports of acute renal failure with increased urea and uric acid concentration, reduced urinary volume and diminished creatinine secretion, in victims that had been stung by *Androctonus*, *Leiurus* and *Buthus* scorpions [6]. Zare et al demonstrated creatinine and BUN increment following *Odonthobuthus doriaes* scorpion venom injection in rabbits [9]. According to the elevation in creatinine and kidney complications, it is clear that *Mesobuthus eupeus* venom in the doses used can cause alterations in the renal function in rabbits. In our previous study, *Me* envenomation induced histopathological abnormalities including; edema, myocytolysis, coagulation

necrosis, and hemorrhage in the heart as well as edema, hemorrhage and vascular thrombus in the lungs of animals [20]. Clinical manifestations of scorpion envenomation are usually complex in nature and can be ascribed mainly to noticeable autonomic nervous system overactivity similar to pheochromocytoma. Many toxins in scorpion venoms can interfere with voltage-gated Na<sup>+</sup> channels and/or voltage-gated and other K<sup>+</sup> channels that result in massive release of autonomic neurotransmitters (described as 'an autonomic storm'). This phenomenon is a major contributor to the pathophysiology of scorpion envenomation [21]. Therefore, renal injury can be due to massive release of catecholamines and resultant vasoconstriction and hypertension. Nevertheless, these lesions may also be caused by other substances in scorpion venom such as cytokines and inflammatory mediators [22, 23]. *Me* venom may also have direct toxic effects on vessel walls. Endothelial cells represent the first cellular barrier to blood-borne toxins that reach the deeper vessel wall layers. These cells are particularly susceptible to toxic insult. Toxins that reach the subendothelial space may cause injury to medial smooth muscle cells and/or adventitial fibroblasts [24].

Our data showed that polyvalent antivenom can prevent and reverse nephrotoxic effects of *Meobuthus eupeus* scorpion venom in rabbits. In group three, immunotherapy prevented renal complications. Antivenom probably neutralizes circulating toxins. In group four, immunotherapy reduced renal complications such as glomerular congestion, dilated vessels of interstitium and focal interstitial congestion in kidneys of all animals. In our previous study, we showed simultaneous administration of antivenom and venom completely prevented clinical signs, hemodynamic disturbances, markers changes, ECG abnormalities and histopathological damage. Delayed immunotherapy gradually ameliorated clinical signs, hemodynamic disturbances and markers changes related to envenomation [25]. In another study, we demonstrated that immunotherapy can neutralize severe inflammatory response induced by *Mesobuthus eupeus* scorpion venom. The time between scorpion poisoning and administration of scorpion antivenom is an essential factor that could limit the clinical efficacy of

immunotherapy, due to the pharmacokinetic characteristics of venom and antivenom. Venom toxins have low molecular weight and diffuse rapidly in tissues, while antivenom elements such as total IgG or immunoglobulin fractions (Fab, F(ab)<sub>2</sub>) have a slower diffusion because of higher molecular weight [26, 27]. Hence, the time between scorpion sting and administration of antivenom is vital and immunotherapy must be commenced as soon as possible in victims with severe envenomation.

## CONCLUSION

Injection of sublethal doses of *Mesobuthus eupeus* scorpion venom induces pathological and biochemical abnormalities in kidney of animals. In addition, intravenous administration of the appropriate dose of polyvalent antivenom as soon as possible in victims stung by *Me* scorpion venom may be beneficial in neutralizing renal toxicity.

## ACKNOWLEDGEMENTS

Author wishes to thanks the Dr Zare mirakabadi and staff of department of Venomous Animals of Razi Vaccine and Serum Research Institute for their kind cooperation.

## REFERENCES

1. Chowell G, Díaz-Dueñas P, Bustos-Saldaña R, Mireles AA, Fet V. Epidemiological and clinical characteristics of scorpionism in Colima, Mexico (2000–2001). *Toxicon*. 2006;47(7):753-8.
2. Gueron M, Ilia R, Margulia G. Arthropod poisons and the cardiovascular system. *The American journal of emergency medicine*. 2000;18(6):708-14.
3. Radmanesh M. *Androctonus crassicauda* sting and its clinical study in Iran. *The Journal of tropical medicine and hygiene*. 1990;93(5):323-6.
4. Ozkan O, Carhan A. The neutralizing capacity of *Androctonus crassicauda* antivenom against *Mesobuthus eupeus* scorpion venom. *Toxicon*. 2008;52(2):375-9.
5. D'Suze G, Salazar V, Díaz P, Sevcik C, Azpurua H, Bracho N. Histopathological changes and inflammatory response induced by *Tityus discrepans* scorpion venom in rams. *Toxicon*. 2004;44(8):851-60.
6. Ismail M, Abd-Elsalam M. Are the toxicological effects of scorpion envenomation related to tissue venom concentration? *Toxicon*. 1988;26(3):233-56.
7. Pipelzadeh MH, Dezfulian A-R, Jalali MT, Mansouri A-K. In vitro and in vivo studies on

- some toxic effects of the venom from *Hemiscorpius lepturus* scorpion. *Toxicon*. 2006;48(1):93-103.
8. Mirakabadi A, Zolfagharian H, Hedayat A, Jalali A. Clinical and biochemical manifestation produced by scorpion (*Hemiscorpius lepturus*) venom in experimental animals. *Journal of Venomous Animals and Toxins including Tropical Diseases*. 2007;13(4):758-65.
  9. Mirakabadi A, Jalali A, Jahromi A, Vatanpur H, Akbary A. Biochemical changes and manifestations of envenomation produced by *Odonthobuthusdoriae* venom in rabbits. *Journal of Venomous Animals and Toxins including Tropical Diseases*. 2006;12(1):67-77.
  10. Ismail M. The treatment of the scorpion envenoming syndrome: the Saudi experience with serotherapy. *Toxicon*. 1994;32(9):1019-26.
  11. De Roodt AR, García SI, Salomón OD, Segre L, Dolab JA, Funes RF, et al. Epidemiological and clinical aspects of scorpionism by *Tityus trivittatus* in Argentina. *Toxicon*. 2003;41(8):971-7.
  12. Hammoudi-Triki D, Lefort J, Rougeot C, Robbe-Vincent A, Bon C, Laraba-Djebari F, et al. Toxicokinetic and toxicodynamic analyses of *Androctonus australis hector* venom in rats: Optimization of antivenom therapy. *Toxicology and applied pharmacology*. 2007;218(3):205-14.
  13. Abroug F, ElAtrous S, Nouria S, Haguiga H, Touzi N, Bouchoucha S. Serotherapy in scorpion envenomation: a randomised controlled trial. *The Lancet*. 1999;354(9182):906-9.
  14. Gueron M, Margulis G, Ilia R, Sofer S. The management of scorpion envenomation 1993. *Toxicon*. 1993;31(9):1071-6.
  15. Bawaskar H, Bawaskar P. Treatment of cardiovascular manifestations of human scorpion envenoming: is serotherapy essential? *The Journal of tropical medicine and hygiene*. 1991;94(3):156-8.
  16. Balozert L, Bucherl W, Buckley E. Venomous animals and their venoms. 3: Venomous invertebrates. *Venomous animals and their venoms: Venomous invertebrates*. 1971;3: 349-71.
  17. NunanErA, Moraes MF, Cardoso VN, Moraes-Santos T. Effect of age on body distribution of Tityustoxin from *Tityus serrulatus* scorpion venom in rats. *Life Sciences*. 2003;73(3):319-25.
  18. Nunan E, Arya V, Hochhaus G, Cardoso V, Moraes-Santos T. Age effects on the pharmacokinetics of tityustoxin from *Tityus serrulatus* scorpion venom in rats. *Brazilian journal of medical and biological research*. 2004;37(3):385-90.
  19. Martins A, Monteiro H, Júnior E, Menezes D, Fonteles M. Effects of *Crotalus durissus cascavella* venom in the isolated rat kidney. *Toxicon*. 1998;36(10):1441-50.
  20. Zayerzadeh E, Koohi M, ZareMirakabadi A, Purkabireh M, Kassaian S, Rabbani S, et al. Cardiopulmonary complications induced by Iranian *Mesobuthus eupeus* scorpion venom in anesthetized rabbits. *Journal of Venomous Animals and Toxins including Tropical Diseases*. 2010;16(1):46-59.
  21. Gwee MC, Nirthanan S, Khoo HE, Gopalakrishnakone P, Kini RM, Cheah LS. Autonomic effects of some scorpion venoms and toxins. *Clinical and Experimental Pharmacology and Physiology*. 2002;29(9):795-801.
  22. D'suze G, Moncada S, González C, Sevcik C, Aguilar V, Alagón A. Relationship between plasmatic levels of various cytokines, tumour necrosis factor, enzymes, glucose and venom concentration following *Tityus* scorpion sting. *Toxicon*. 2003;41(3):367-75.
  23. Fukahara Y, Reis M, Dellalibera-Joviliani R, Cunha F, Donadi E. Increased levels of IL-1b, IL-6, IL-8, IL-10 and TNF-a in patients moderately or severely envenomed by *Tityus serrulatus* scorpion sting. *Toxicon*. 2003;41:49-55.
  24. Curtis D, John B. *Essentials of toxicology*. McGraw-Hill Co. Inc. New York-USA; 2003.p.281-3.
  25. Zayerzadeh E, Koohi MK, Mirakabadi AZ, Fardipoor A, Kassaian SE, Rabbani S, et al. Amelioration of cardio-respiratory perturbations following *Mesobuthus eupeus* envenomation in anesthetized rabbits with commercial polyvalent F (ab') 2 antivenom. *Toxicon*. 2012;59(2):249-56.
  26. Ismail M, Abd-Elsalam M. Pharmacokinetics of 125 I-labelled IgG, F (ab') 2 and Fab fractions of scorpion and snake antivenins: merits and potential for therapeutic use. *Toxicon*. 1998;36(11):1523-8.
  27. Krifi, MN, Kharrat H, Zeghal K, Abdouli M, Abroug F, Bouchoucha S. Development of an ELISA for the detection of scorpion venoms in sera of humans envenomed by *Androctonus australis garzonii* (*Aag*) and *Buthu soccitamus tunetanus* (*Bot*): correlation with clinical severity of envenoming in Tunisia. *Toxicon*. 1998;36:887- 900.