

Original Article**A Comparative Analysis of Saffron and Methylprednisolone on Bleomycin-Induced Pulmonary Fibrosis in Rats**

Mehrzad Bahtouee¹, Hossein Fatemikia², Ali Movahed³, Abdolhamid Esmaili⁴, Yaghoob Hassan⁵,
Mohammad Zarei¹, Ramin Seyedian^{*6}

Received: 28.01.2018

Accepted: 13.03.2018

ABSTRACT

Background: The purpose of this study was to compare the effects of saffron and methylprednisolone on bleomycin-induced pulmonary fibrosis in rats.

Methods: This study was conducted in Bushehr, southern Iran in 2017. The animals were divided into four groups of five rats each. Three groups were injected with a single intratracheal dose of bleomycin (5 mg/kg). The fourth group was administered with normal saline at the same volume (200 µl). Saffron extract dissolved in water was given to one group (100 mg /body weight) orally while intraperitoneal injection of methylprednisolone (2.5 mg/kg) injected to another one for 16 days. The rats were sacrificed 28 days following surgery and their right and left lungs were removed and washed for measuring lung indices, myeloperoxidase activities and finally histopathological examination.

Results: Injection of bleomycin caused decrement of body weight aggravated by intraperitoneal methylprednisolone treatment. Lung indices were increased in the bleomycin-treated group compared with the control, while methylprednisolone, unlike saffron, had no preventive effects on it. Both saffron and methylprednisolone treatment prevented the increase in lung myeloperoxidase as a destructive enzyme. In addition, excessive collagen deposition and thickening of alveolar septa were significantly prevented with saffron treatment as compared to methylprednisolone injection following hematoxylin and eosin staining.

Conclusion: Saffron with established antioxidant properties could prevent some detrimental effects in bleomycin-induced pulmonary fibrosis even more than methylprednisolone injection known as a standard therapy in this murine model. More investigations must be carried out to examine the beneficial or harmful effects of this remedy.

Keywords: Fibrosis, Lung, Methylprednisolone, Saffron.

IJT 2018 (3): 9-13

INTRODUCTION

Idiopathic pulmonary fibrosis (IPF) is considered to be a chronic and developing lung disorder with poor prognosis leading to death among all interstitial lung diseases. It usually affects people over 50 yr old with median survival of 2-4 yr after medical diagnosis [1]. Unfortunately, there is no effective remedy to overcome the fibrotic process induced by this disorder. Pulmonary fibrosis can be produced by intratracheal injection of bleomycin as one of the best animal model resembling IPF. In this model, the disorder is well characterized and clinically relevant to the original disease [2].

Methyl-prednisolone is known as an effective corticosteroid drug used for treatment of chronic lung diseases including idiopathic pulmonary fibrosis since 50 years ago [3]. Huge fibrosis without significant inflammation will not be cleared by using corticosteroid therapy in elderly patients [4].

The saffron (*Crocus sativus*) is collected and dried as flavor for food all over the world, especially in northeastern of Iran. This plant has significant antioxidant, antinociceptive, cardio protective and anti-inflammatory effects [5, 6]. Lung transplantation is the final procedure to

1. Department of Internal Medicine, Bushehr University of Medical Sciences, Bushehr, Iran.

2. Departments of Physiology, School of Medicine, Shiraz University of Medical Sciences, Shiraz, Iran.

3. PhD of Biochemistry, Persian Gulf Tropical Research Center, Bushehr University of Medical Sciences, Bushehr, Iran.

4. Department of Pathology, Bushehr University of Medical Sciences, Bushehr, Iran.

5. BSc of Nutrition, Student Research Committee Center, Bushehr University of Medical Sciences, Bushehr, Iran.

6. Department of Pharmacology, Bushehr University of Medical Sciences, Bushehr, Iran.

*Corresponding author: E-mail: raminsyedian@gmail.com

increase the life span in IPF since effectiveness of the different drugs to overcome this disorder is questionable. Antioxidant properties of different plants like curcumin and naringin could attenuate the fibrotic process [7, 8].

The purpose of this preliminary study was to evaluate the antifibrotic effects of saffron on bleomycin-induced fibrosis in rats by measuring myeloperoxidase level as one of the destructive enzymes in lung tissue homogenates in addition to histopathological evaluation. Moreover, the effects of saffron on bleomycin-induced fibrosis will be compared with methylprednisolone therapy as a standard treatment in rats [9].

MATERIALS AND METHODS

Animals

Male Wistar rats (200–250 gr) were purchased from Animal Breeding Center, Shiraz, Iran in 2017. They were housed in groups of three in polycarbonate cages with 12-h light and dark cycles and had free access to water and normal laboratory chow in animal house of Bushehr University of Medical Sciences.

All experimental procedures were approved by the Ethical Committee for animal care of this university.

Chemical Agents

Aqueous Saffron solution (10 g dissolved in 100 ml of distilled water) was kindly donated from Iranian Zardband Pharmaceutical Company. Myeloperoxidase ELISA assay kit was purchased from ZellBio GmbH Company of life sciences (Germany). Methylprednisolone acetate ampule (40mg/ml) was purchased from Iranian Caspian Tamin Company.

Experimental Protocol

Rats were anesthetized with intraperitoneal injection of ketamine (100mg/kg) and xylazine (10 mg/kg) and placed supine on the heated operating table to keep the temperature at 37 °C monitored with a rectal tube connected to a thermistor (Physitemp BAT-12; Texas Scientific Instruments, San Antonio, Texas, USA). The animals were randomly divided into four groups of five rats each, i.e., negative control (NC), positive control (PC), saffron (S) and methylprednisolone (MP). Rats in the group NC were instilled normal saline (200µl) intratracheally, and the other groups received bleomycin (5mg/kg dissolved in NS at the same volume) to induce bleomycin mediated pulmonary fibrosis. The animals in MP group were treated with 2.5 mg/kg of methylprednisolone intraperitoneally

for 16 d while normal saline solution was injected into the other groups with the same schedule. Rats in group S were treated with 100mg/kg saffron solution orally (once daily) while the other groups received water alone [9-11]. At the end of our study (28 days following bleomycin injection), the animals were anesthetized and sacrificed. The lungs were removed and washed with cold normal saline. The left lungs were kept in 10% formaldehyde for histological analysis by using Hematoxylin and Eosin staining. The right lungs were minced and reserved at -80 °C until analysis.

For light microscopic analysis, small pieces were fixed in 10% formaldehyde and placed in paraffin. Tissue segments were stained with H&E to find out the general morphology and detection of pulmonary fibrosis under a photomicroscope (Olympus BX51 Tokyo, Japan).

Lung samples were homogenized in a (10%) phosphate buffer on ice powder. The supernatants were collected and stored at -20 °C after centrifugation (2000 gr for 20 min). Myeloperoxidase activity was measured with the Commercial kit (Zellbio Company, Germany) [8].

Statistical Analysis:

Statistical analysis was performed using SPSS, version 16.0 (Chicago, IL, USA). Data are presented as mean ± SD. Statistical differences between groups were analyzed by one-way analysis of variance, followed by Tuckey multiple comparison tests. *P*-value <0.05 was considered as statistically significant.

RESULTS

Body Weight and Lung Indices

A significant weight decrement in methylprednisolone treated rats was observed, peaking at day 15, as compared with the other groups (Fig. 1A). There was a statistically significant increase (*P*<0.05) in lung indices (dividing lung weight by body weight, multiplying by 100) of bleomycin group when compared to the normal saline. Moreover, saffron instillation (100mg/kg) showed a notable decrease in this parameter compared to bleomycin group, while methylprednisolone treatment had no effects (*P*<0.05).

Myelo Peroxidase Activity

This parameter increased significantly following administration of bleomycin as compared with the control (0.43 IU/ml versus 0.166 IU/ml). Saffron consumption and methylprednisolone treatment showed notable decrease of this marker (0.21 IU/ml and 0.29 IU/ml) respectively (*P*<0.05) (Fig. 2)

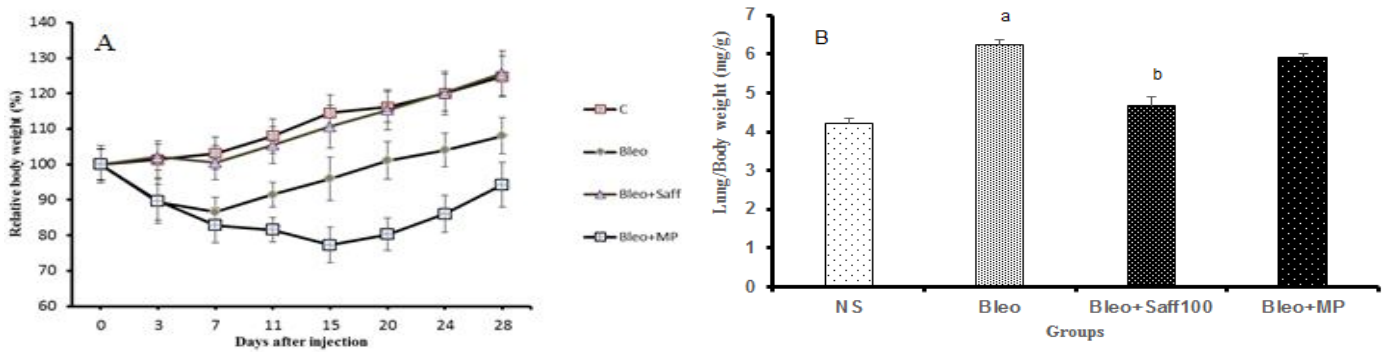


Figure 1. Effects of saffron and methylprednisolone treatment on body weight (1A) and lung indices (1B) in rats with fibrosis. Data are given as mean \pm SD from five rats in each group. ^a $P < 0.05$ compared with the control group, ^b $P < 0.05$ compared with bleomycin group.

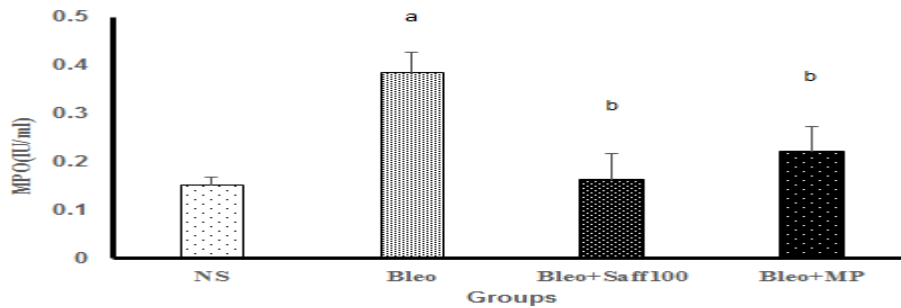


Figure 2. Effects of normal saline, bleomycin, bleomycin plus saffron and finally bleomycin plus methylprednisolone on MPO in lung homogenates. Data are presented as mean \pm SD ($n=5$). Treatment with saffron and methylprednisolone lowered the lung MPO activity on day 28 versus bleomycin group. ^a $P < 0.05$ versus saline control group; ^b $P < 0.05$ versus bleomycin group.

Histopathological Differences

The lungs were examined with light microscope at the end of study. Contrary to control group, in bleomycin-treated rats, narrowing of alveolar sacs, gross thickening of alveolar septa, and accumulation of inflammatory cells were seen (Fig 3A-B).

Furthermore, saffron treatment exhibited protection against bleomycin-induced detrimental changes including decreased cellular infiltration and thickening of alveolar septa (Fig. 3 D). In addition, in methyl-prednisolone group less protective effects on destructive pathological changes were seen compared to saffron (Fig. 3 C).

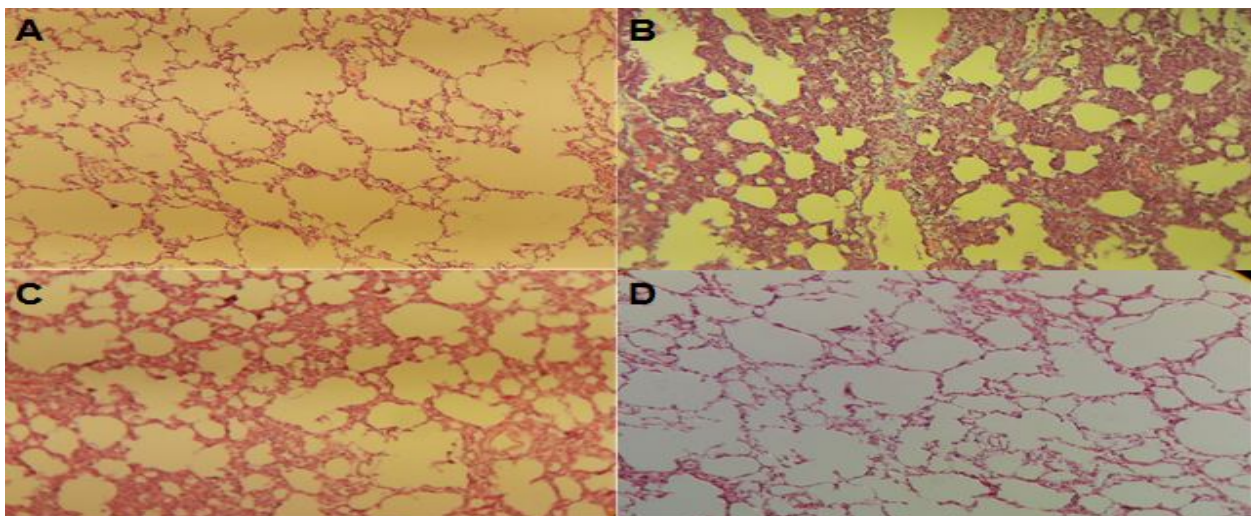


Figure 3. Effects of saffron and methylprednisolone on bleomycin-induced lung injury on prepared lung tissue with Hematoxylin and Eosin staining. A) Normal saline-treated group on day 28 showing no pathological alterations. B) Bleomycin group, with marked inflammation in lung tissues and increasing lung septa. C) Bleomycin/Methylprednisolone group showing moderate inflammation in lung tissues. D) Bleomycin/Saffron-treated group with mild thickening of septa.

DISCUSSION

Idiopathic pulmonary fibrosis is characterized by an unknown lung disorder with a poor prognosis. Airway inflammation and lung injuries due to cytokine release are involved in fibrotic nature. Overall, Corticosteroids like methyl-prednisolone has been introduced as an accepted anti-inflammatory therapy in animal models of bleomycin-induced pulmonary fibrosis [12]. Weight decline due to acute injury in lung parenchyma is a common observation in this animal model [13].

In the present study, methylprednisolone treatment decreased significantly the body weight peaking at 15 d as compared to other groups following the same procedure (Fig. 1). Based on this study, this agent had a poor capacity for maintaining weight gain and general well-being in the murine fibrotic model. Saffron may be used as an antitussive, anticatarrhal, carminative and claimed to have aphrodisiac properties [14].

The ameliorative effects of saffron on bleomycin-induced fibrosis in murine models were confirmed in our previous experiment [11]. Contrary to methylprednisolone, the measure of the body weight had no change with oral saffron treatment during our study compared to control (Fig. 1A). It is indicated of the beneficial effects of this remedy in maintaining weight gain similar to previous studies on plants extract [15]. On the contrary to methylprednisolone treatment, saffron had no statistically significant differences in lung indices as compared with the control ($P < 0.05$), showing its prominent antifibrotic properties (Fig. 1B). It suggests similarities between this plant and other established antifibrotic remedies including apigenin, naringin, and baicalein against bleomycin-induced fibrosis [16, 17].

Lung myeloperoxidase measurement (U/mg protein) is used to reveal leukocyte accumulation and activity since these trapped immune cells secrete different cytokines and reactive oxygen species leading to the repair process [18, 19].

Notably, increased MPO activity in bleomycin-exposed rat as compared to the control (0.43 U/mg versus 0.16 U/mg) indicates the induction of lung injury. Importantly, treatment with saffron significantly decreased the activity of this enzyme compared with bleomycin-treated rats (0.21 U/mg versus 0.43 U/mg). The preventive effects of low dose of dexamethasone were studied on bleomycin-induced lung fibrosis [20]. Methylprednisone treatment (2.5 mg/kg) after 16 d significantly reduced lung MPO activity, while dexamethasone

(0.5 mg/kg) showed no effects [20]. This finding may be stemmed from differences between their doses, salt retention and finally half-lives [21].

Fibroblasts as the producers of collagen in pulmonary fibrosis originate from the epithelial mesenchymal-transition in experimental animal fibrosis [22, 23]. Saffron diminished the formation and extent of the fibrotic process, induced by bleomycin. This effect was obviously more than methylprednisolone treatment as a standard corticosteroid therapeutic drug. Nonetheless, saffron diminished leukocyte infiltration and alveolar thickness as compared with bleomycin alone (Fig. 3D versus 3C).

CONCLUSION

This preliminary study introduces saffron as a candidate to attenuate the fibrotic process induced by bleomycin in rats. Our findings support the notion of the beneficial effects of this plant on weight gain, lung indices and histopathological alterations compared with methylprednisolone as a standard treatment in murine models [24].

ACKNOWLEDGMENTS

This project was supported by Bushehr University of Medical Sciences (IR.BPUMS.REC.1395.118). The authors have no conflict of interests to declare

REFERENCES

1. King TE, Pardo A, Selman M. Idiopathic pulmonary fibrosis. *Lancet* 2011;378(9807):1949-61.
2. Moore BB, Hogaboam CM. Murine models of pulmonary fibrosis. *Am J Physiol Lung Cell Mol Physiol* 2008;294(2):L152-L60.
3. Flaherty KR, Toews GB, Lynch JP, Kazerooni EA, Gross BH, Strawderman RL, et al. Steroids in idiopathic pulmonary fibrosis: a prospective assessment of adverse reactions, response to therapy, and survival. *Am J Med* 2001;110(4):278-82.
4. King Jr TE, Tooze JA, Schwarz MI, BROWN KR, CHERNIACK RM. Predicting survival in idiopathic pulmonary fibrosis: scoring system and survival model. *Am J Respir Crit Care Med* 2001;164(7):1171-81.
5. Hosseinzadeh H, Younesi HM. Antinociceptive and anti-inflammatory effects of *Crocus sativus* L. stigma and petal extracts in mice. *BMC Pharmacol* 2002;2(1):7.
6. Javadi B, Sahebkar A, Emami SA. A survey on saffron in major Islamic traditional medicine books. *Iran J Basic Med Sci* 2013;16(1):1.
7. Xu M, Deng B, Chow Y-l, Zhao Z-z, Hu B. Effects of curcumin in treatment of experimental pulmonary

- fibrosis: a comparison with hydrocortisone. *J Ethnopharmacol* 2007;112(2):292-9.
8. Turgut NH, Kara H, Elagoz S, Deveci K, Gungor H, Arslanbas E. The Protective effect of naringin against bleomycin-induced pulmonary fibrosis in Wistar rats. *Pulm Med* 2016;2016.
9. Aytemur ZA, Hacievliyagil SS, Iraz M, Samdanci E, Ozerol E, Kuku I, et al. Effects of iloprost on bleomycin-induced pulmonary fibrosis in rats compared with methyl-prednisolone. *Rev Port Pneumol* 2012;18(6):272-7.
10. Asdaq SMB, Inamdar MN. Potential of *Crocus sativus* (saffron) and its constituent, crocin, as hypolipidemic and antioxidant in rats. *Appl Biochem Biotechnol* 2010;162(2):358-72.
11. Bahtouee M, Fatemikia H, Pourkhalili K, Kim E, Rahimi HR, Tavosi Z, et al. Saffron Protection against Bleomycin-Induced Pulmonary Fibrosis in Rats. *Iran J Toxicol* 2017;11(6):7-12.
12. Dik W, McAnulty R, Versnel M, Naber B, Zimmermann L, Laurent G, et al. Short course dexamethasone treatment following injury inhibits bleomycin induced fibrosis in rats. *Thorax* 2003;58(9):765-71.
13. Izbicki G, Segel M, Christensen T, Conner M, Breuer R. Time course of bleomycin-induced lung fibrosis. *Int J Clin Exp Pathol* 2002;83(3):111-9.
14. Hosseinzadeh H, Ghenaati J. Evaluation of the antitussive effect of stigma and petals of saffron (*Crocus sativus*) and its components, safranal and crocin in guinea pigs. *Fitoterapia* 2006;77(6):446-8.
15. Şener G, Topaloğlu N, Şehirli AÖ, Ercan F, Gedik N. Resveratrol alleviates bleomycin-induced lung injury in rats. *Pulm Pharmacol Ther* 2007;20(6):642-9.
16. Gao Y, Lu J, Zhang Y, Chen Y, Gu Z, Jiang X. Baicalein attenuates bleomycin-induced pulmonary fibrosis in rats through inhibition of miR-21. *Pulm Pharmacol Ther* 2013;26(6):649-54.
17. Chen L, Zhao W. Apigenin protects against bleomycin-induced lung fibrosis in rats. *Exp Ther Med Journal* 2016;11(1):230-4.
18. Tarnell EB, Oliver BL, Johnson GM, Watts FL, Thrall RS. Superoxide anion production by rat neutrophils at various stages of bleomycin-induced lung injury. *Lung* 1992;170(1):41-50.
19. Nicholas C, Batra S, Vargo MA, Voss OH, Gavrillin MA, Wewers MD, et al. Apigenin blocks lipopolysaccharide-induced lethality in vivo and proinflammatory cytokines expression by inactivating NF- κ B through the suppression of p65 phosphorylation. *The J Immunol* 2007;179(10):7121-7.
20. Chen F, Gong L, Zhang L, Wang H, Qi X, Wu X, et al. Short courses of low dose dexamethasone delay bleomycin-induced lung fibrosis in rats. *Eur J Pharmacol* 2006;536(3):287-95.
21. Becker DE. Basic and clinical pharmacology of glucocorticosteroids. *Anesth Prog* 2013;60(1):25-32.
22. Kim SN, Lee J, Yang H-S, Cho J-W, Kwon S, Kim Y-B, et al. Dose-response effects of bleomycin on inflammation and pulmonary fibrosis in mice. *Toxicol Res* 2010;26(3):217.
23. Tanjore H, Xu XC, Polosukhin VV, Degryse AL, Li B, Han W, et al. Contribution of epithelial-derived fibroblasts to bleomycin-induced lung fibrosis. *Am J Respir Crit Care Med* 2009;180(7):657-65.
24. Walter N, Collard HR, King Jr TE. Current perspectives on the treatment of idiopathic pulmonary fibrosis. *Ann Am Thorac Soc* 2006;3(4):330-8.