

## Rapid Revival of a Patient after very Severe Metabolic Acidosis: A Case Report

Sajad Ahmadi<sup>1</sup>, Samad Shams Vahdati<sup>2\*</sup>, Henghameh Khadivi Heris<sup>3</sup>, Mohammadali Khajehee<sup>4</sup>

Received: 14.07.2012

Accepted: 13.09.2012

### ABSTRACT

**Background:** Metabolic acidosis is a fatal finding in trauma patients that complicates the process of resuscitation.

**Case:** The case was a 37-year-old man with open fracture in both legs and fracture in second lumbar vertebral (L2). The serial arterial blood gas (ABG) test results showed a pH value of 6.7 indicating a very severe and special case of metabolic acidosis. The rate of mortality for such a case was very high. The patient was treated with sodium bicarbonate and successfully revived after four hours post treatment and metabolic acidosis was resolved.

**Conclusion:** This indicated that bicarbonate administration is useful for very severe cases. The good condition of the patient after survival from the severe acidemia allowed for extubation.

**Keywords:** Metabolic Acidosis, Resuscitation, Trauma Patients.

IJT 2013; 779-781

### INTRODUCTION

Excessive acid production and loss of body alkali result in a state referred to as metabolic acidosis. This state can be recognized by serial arterial blood gas (ABG) analysis. A pH value of less than 7.35 and serum bicarbonate ( $\text{HCO}_3^-$ ) concentration of less than 18mEq/L indicate metabolic acidosis (1). Severe metabolic acidosis is life-threatening. A pH value below 7.1 is an emergency due to the risk of cardiac arrhythmias. Mortality rate of severely injured patients with metabolic acidosis is twice as much as that of patients who do not have metabolic acidosis (2). In this study, a case of a patient with dramatically high acidosis as well as the treatment procedure is reported. For this purpose, informed consent was obtained from the patient.

### CASE REPORT

A 37-year-old man referred to the emergency department with multiple traumas. He had fallen from a height of 9 meters 4 hours before being admitted to the Emergency Department of Imam Reza Hospital, Tabriz, Iran. Upon admission, the patient awake and orientated. His vital signs were: blood pressure (BP): 90/60, pulse rate (PR): 150, respiratory rate (RR): 21, body temperature (BT): 37, and oxygen ( $\text{O}_2$ ) saturation: 98%.

On physical exam, the conjunctive was pale and the head and neck were normal. The chest was tender and the lung was symmetrically clear. The abdominal was without tenderness, but he had tenderness and pain on lumbar vertebral. Three open fractures were observed in his limb. There was a fracture in proximal side

1. Resident of Emergency Medicine, Tabriz University of Medical Sciences, Tabriz, Iran.

2. Department of Emergency Medicine, Tabriz University Of Medical Sciences, Tabriz, Iran.

3. Intern Ship, Tabriz University of Medical Sciences, Tabriz, Iran.

4. Emergency Physician, Sina Hospital, Tabriz University of Medical Sciences, Tabriz, Iran.

\*Corresponding Author E-mail: shams@tbzmed.ac.ir

of his right tibia while there were two open fractures in his left tibia. Pulse was not palpable in any of his legs.

In the fast examination, no fluid was found in the abdomen and pelvic. The test results implied no bleeding in the abdominal and pelvic sections. Lateral lumbar graphy (Figure 1.a) showed a fracture in the second lumbar vertebral (L2). Also computed tomography (CT) scan confirmed the fracture (Figure 1.b). Due to severe trauma, brain CT scan was requested and the images showed that the brain was normal without skeletal and parenchymal findings.

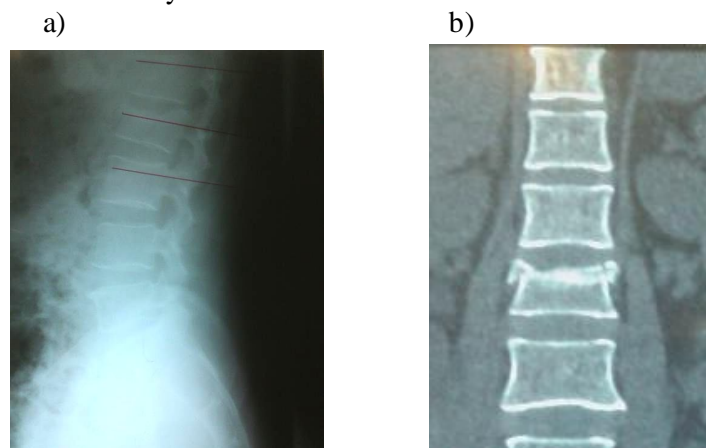
Due to low BP, high PR, and low hemoglobin, the patient received 4 units of pack cell and 2 units of fresh frozen plasma (FFP). Serial ABG results (Table 1) indicated that the patient was going to a metabolic acidosis state. Then, he was intubated because of shock state and dyspnea.

After the first ABG test, the patient was diagnosed with critically metabolic

acidosis. Bicarbonate was administrated at 1mEq/kg bolus and 0.5mEq/kg/hr doses. The ABG tests were performed every 30 minutes. Rapid Shallow Breathing Index was 90 breaths/min/L. Therefore, the patient was extubated.

## DISCUSSION

Hemorrhagic shock is a consequence of rapid and considerable loss of intravascular volume. This condition may result in hemodynamic instability, decreased tissue perfusion, cellular hypoxia, and organ damage which may end in death. In traumatized patients, substantial blood loss is the main cause of shock (3). In hemorrhagic shock, body fails to provide adequate oxygen and may not be able to compensate the tissue perfusion. The general sign of hemorrhagic shock is a loss of blood pressure. Hemorrhagic shock can result in a change of the level of lactic acid, pyruvic acid, glucose,  $\text{HCO}_3^-$ , and  $\text{H}^+$  (4).



**Figure 1.** a) Lateral lumbar graphy, b) Lumbar CT scan

**Table1.** Several ABG test results in chronological order every 30 minutes

ABG results	1st	2nd	3 <sup>rd</sup>	4 <sup>th</sup>	5 <sup>th</sup>	6 <sup>th</sup>
pH	6.7	6.7	6.9	7.0	7.1	7.1
PCO <sub>2</sub>	49.9	70.3	71.0	71.1	55.0	45.0
HCO <sub>3</sub>	6.6	8.4	14.1	15.4	16.8	13.3

This condition can lead to metabolic acidosis. In other words, metabolic acidosis is an important sign of inadequate oxygen delivery and requires a more aggressive resuscitation. PH level of the blood is a diagnostic criterion for the level of acidity and the degree of severity in metabolic acidosis. A blood pH less than 7.2 is life threatening and the patients are diagnosed with acidemia where administration of bicarbonate is necessary to improve the pH value. In this case report, our patient had acute bleeding due to multiple fractures of the legs. He experienced a hemorrhagic shock and went to metabolic acidosis. The first test showed that his blood pH was 6.7 indicating a very severe case of metabolic acidosis putting him in a distinctive situation with high probability of death. No ionic gap test was done to confirm that the case had lactic acidosis. However, hemorrhagic shock is normally followed by an increase in blood lactate and can result in lactic acidosis.

### CONCLUSION

The death rate in patients with severe metabolic acidosis is almost twice as much as that of patients without metabolic acidosis (2). Furthermore, few patients with lactic acidosis and a pH level of less than 6.8 survive (5). In this study, the patient had an initial blood pH of 6.7 and he survived because of bicarbonate treatment. This shows that emergency physicians can manage shock state if it is

rapidly diagnosed. Another outcome of this study is that bicarbonate administration can be effective for severe cases of metabolic acidosis. The patient was extubated in the Emergency Department of Imam Reza Hospital and was sent to a hospital for orthopedic treatments.

### ACKNOWLEDGEMENTS

The authors would like to express their gratitude to Tabriz University of Medical Sciences that supported this case report.

### REFERENCES

1. Charles JC, Heilman RL. Metabolic acidosis. Hospital Physician. 2005;41(3):37-42.
2. Gunnerson K, Saul M, He S, Kellum J. Lactate versus non-lactate metabolic acidosis: a retrospective outcome evaluation of critically ill patients. Critical Care. 2006;10(1):R22.
3. Gutierrez G, Reines HD, Wulf-Gutierrez ME. Clinical review: hemorrhagic shock. CRITICAL CARE-LONDON-. 2004;8:373-81.
4. Halmagyi D, Irving M, Varga D. Effect of adrenergic blockade on the metabolic response to hemorrhagic shock. Journal of Applied Physiology. 1968;25(4):384-9.
5. Omar AS, ur Rahman M, Abuhasna S. Reported survival with severe mixed acidosis and hyperlactemia after toluene poisoning. Saudi Journal of Anaesthesia. 2011;5(1):73-5.