

Effects of lead nitrate on histo-cytological alterations of corpuscles of Stannius of stinging catfish, *Heteropneustes fossilis*

Rubi Rai¹, Diwakar Mishra², Sunil Kumar Srivastav¹, Nobuo Suzuki³, Ajai Kumar Srivastav^{1*}

Received: 21.01.2013

Accepted: 04.02.2013

ABSTRACT

Background: The present study investigated the effects of lead nitrate on the histo-cytological changes in the corpuscles of Stannius (CS) of *Heteropneustes fossilis*.

Methods: Catfish, *Heteropneustes fossilis* were subjected to 657.6 mg/L and 164.4 mg/L of lead nitrate for 96 h and 28 days, respectively. Blood from fish was collected on 24, 48, 72 and 96 h in short-term and after 7, 14, 21, and 28 days in long-term experiment. Blood was collected for analysis of calcium levels and CS were fixed for histological studies.

Results: Plasma calcium levels of the fish remain unaffected at 24 h. The levels decrease after 48 h which persists till 96 h. Plasma calcium levels of the fish exposed to lead for 7 days exhibit a decrease which persists progressively till 28 days.

After 96 h, AF-positive cells of CS exhibit increased granulation. No change in the nuclear volume of these cells has been noticed. An increased nuclear volume has been recorded in the AF-negative cells of CS of 96 h lead exposed fish. After 14 days, the nuclear volume of AF-positive cells decreases. Heavy accumulation of secretory granules and decrease in the nuclear volume of AF-positive cells have been recorded after 21 days which pronounced after 28 days. Moreover, few degenerating cells have also been encountered. AF-negative cells of CS exhibit an increase in the nuclear volume after 21 and 28 days lead treatment.

Conclusion: Present findings suggest that exposure of the lead to catfish *Heteropneustes fossilis* caused CS inactivity.

Keywords: Corpuscles Of Stannius, Heavy Metal, Lead, Plasma Calcium, Teleost.

IJT 2013;823-830

INTRODUCTION

Lead is a naturally occurring heavy metal which has been used in various ways including mining, smelting, refining, gasoline, battery manufacturing, electrical wiring, soldering, painting, ceramic glazing and the making of stained glass. Due to its non-degradable nature, it gets into our environment and eventually enters the human and animal's blood stream. There from, it is accumulated in soft tissues such as liver, kidneys, nervous

system and the brain. In fishes, fish mortality (1) and accumulation of lead in various tissues (2, 3) and alterations in biochemical and hematological parameters (4) have been reported. Moreover, lead-induced changes in the histological structure of gills liver and kidneys have also been reported (5-9).

In fish inhabiting freshwater, blood ionic concentrations are maintained at much higher levels than those of the ambient water. Hence, they constantly face osmotic inflow of water and diffusional

1. Department of Zoology, D.D.U. Gorakhpur University, Gorakhpur 273 009, India.

2. Department of Zoology, Government Girls P.G. College, Ghazipur (U.P.), India.

3. Noto Marine Laboratory, Institute of Nature and Environmental Technology, Kanazawa University, Ogi, Noto-cho, Ishikawa 927-0553, Japan.

Corresponding Author: E-mail: ajaiksrivastav@hotmail.com

losses of ions across the body surface and gill epithelium. A disturbed hydromineral balance of the body fluids of fish is one of the most conspicuous phenomena observed during stress as there exists an intimate relationship between the surrounding water and the body fluids. There also exist few studies regarding the interaction of lead with calcium homeostasis in mammals and birds. However, there exists a single report from fish regarding the effects of lead on plasma calcium (10). To the best of our knowledge there exists no study regarding the effect of lead on the corpuscles of Stannius of fish. Hence, in this study an attempt has been made to investigate the impact of lead nitrate on the plasma calcium and corpuscles of Stannius of a catfish, *Heteropneustes fossilis*.

MATERIALS AND METHODS

Freshwater stinging catfish *Heteropneustes fossilis* (after two weeks acclimatization) were subjected to 657.6 mg/L (0.8 of 96 h LC₅₀) and 164.4 mg/L (0.2 of 96 h LC₅₀) of lead nitrate for short-term and long-term, respectively. Concurrently, a control group was also run. The media (both control and experimental) were changed every 24 h. The fish were sacrificed at 24, 48, 72 and 96 h in short-term experiment and at 7, 14, 21 and 28 days in long-term experiment. Blood was collected by sectioning of caudal peduncle and oozing blood was collected in heparinized eppendorf tubes. Plasma calcium levels were determined (from six samples from each group –control and

experimental at each interval) by using Sigma kit (Sigma Chemical Co., kit # 587 A). After collection of blood samples the corpuscles of Stannius along with the adjoining portion of kidney were removed from the fish and fixed in aqueous Bouin's fluid. Tissues were routinely processed in graded series of alcohols, cleared in xylene and embedded in paraffin wax. Serial sections were cut at 6 µm. Nuclear indices (maximal length and maximal width) were taken with the aid of ocular micrometer and then the nuclear volume was calculated as –

$$\text{volume} = 4/3\pi ab^2$$

where 'a' is the major semiaxis and 'b' is the minor semiaxis. In the gland, when there are degenerating nuclei, only the indices of intact nuclei were measured.

All data were presented as the mean ± S.E. of six specimens and Student's t test was used to determine statistical significance. In all studies, the experimental group was compared to its specific time control group.

RESULTS

After short-term lead exposure, the plasma calcium levels of the fish were unaffected at 24 h. The levels decreased after 48 h and persisted till the end of the experiment (96 h) (Fig. 1). The plasma calcium levels of the fish exposed to lead for 7 days exhibited a decrease (Fig. 2). This decrease persisted progressively till the close of the experiment (28 days) (Fig. 2).

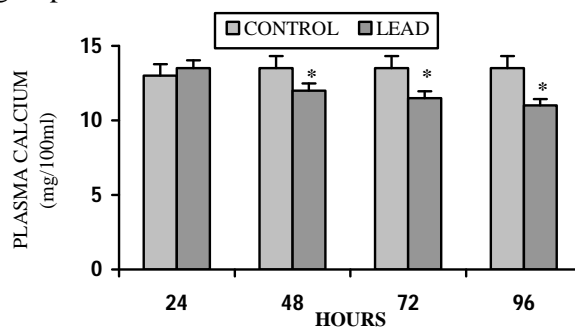


Figure 1. Plasma calcium levels of short-term lead nitrate treated *Heteropneustes fossilis*. Values are mean ± S.E. of six specimens. Asterisk indicates significant differences ($P < 0.05$) from control.

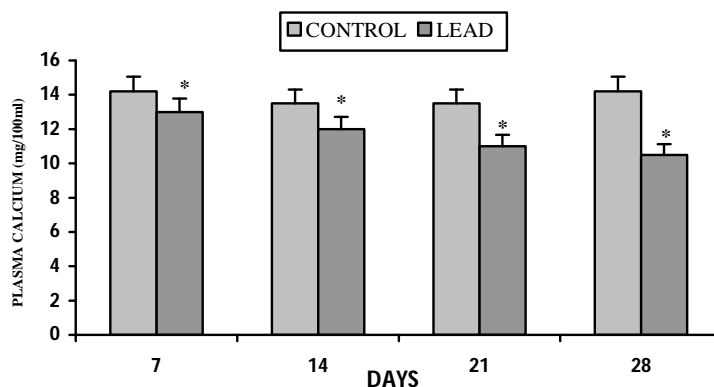


Figure 2. Plasma calcium levels of long-term lead nitrate treated *Heteropneustes fossilis*. Values are mean \pm S.E. of six specimens. Asterisk indicates significant differences ($P < 0.05$) from control.

The corpuscles of Stannius of control *H. fossilis* exhibit two types of cells namely- AF-positive and AF-negative cells (Fig. 3). Up to 72 h after exposure of the fish to lead, the AF-positive cells of corpuscles of Stannius exhibit no histological change. After 96 h, these cells exhibit increased granulation (Fig. 4). No change in the nuclear volume of AF-positive and AF-negative cells has been noticed.

There is no change in the AF-positive cells up to 7 days following lead exposure. After 14 days, the nuclear

volume of these cells decreases (Fig. 5). The heavy accumulation of secretory granules (Fig. 6) as well as a decrease in the nuclear volume of AF-positive cells (Fig. 5) have been recorded after 21 days of lead exposure. These changes are more pronounced after 28 days. Moreover, few degenerating cells have also been encountered (Fig. 7). No change has been noticed up to 14 days in the AF-negative cells of the fish exposed to lead. These cells exhibit an increase in the nuclear volume after 21 and 28 days lead treatment (Fig. 8).

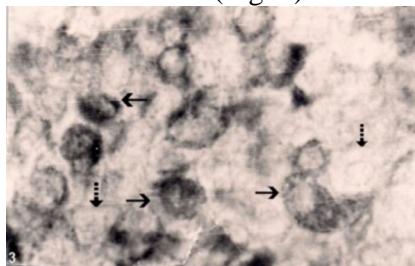


Figure 3. Corpuscles of Stannius of control *Heteropneustes fossilis* showing AF-positive (arrows) and AF-negative (broken arrows) cells. Aldehyde fuchsin X 800.

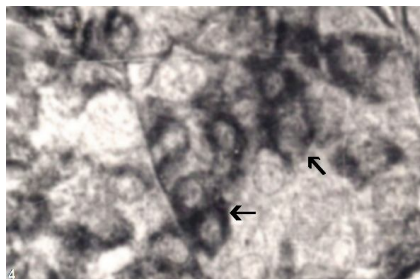


Figure 4. Corpuscles of Stannius of 96 h lead nitrate treated *Heteropneustes fossilis* exhibiting increased granulation (arrows) in AF-positive cells. Aldehyde fuchsin X 800.

DISCUSSION

Lead exposure to *H. fossilis* provoked hypocalcemia. This derives support from the studies of Rogers *et al.* (10) who have also reported hypocalcemia in lead-exposed rainbow trout. This is in agreement with the reports of other investigators who have also observed decreased blood/ plasma calcium content of fish after treatment with either aldrin (11), malachite green (12), cadmium (13,14,15), propoxur (16), formothion (16),

chlorpyrifos (17), deltamethrin (18), cypermethrin (19) or botanical pesticides (20,21). On the contrary, elevation of plasma calcium concentrations has also been reported by other workers from the fish exposed to various toxicants (22-25). However, no effect on plasma calcium level has been noticed in methoxychlor exposed Northern puffer *Sphaeroides maculatus* (26), DDT treated flounders *Platichthys flesus* (27) and bifenthrin treated rainbow trout *O. mykiss* (28).

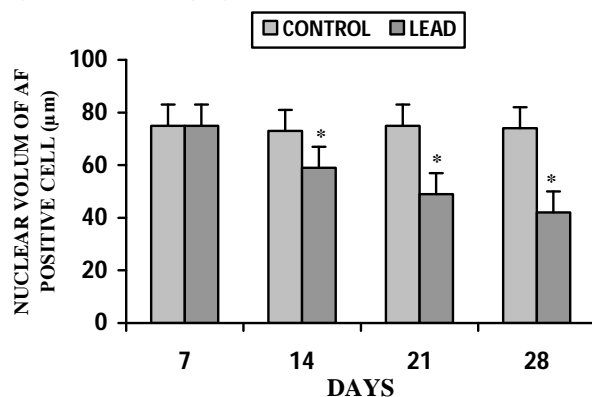


Figure 5. Nuclear volume of AF-positive cells of long-term lead nitrate exposed *Heteropneustes fossilis*. Values are mean \pm S.E. of six specimens. Asterisk indicates significant differences ($P < 0.05$) from control.

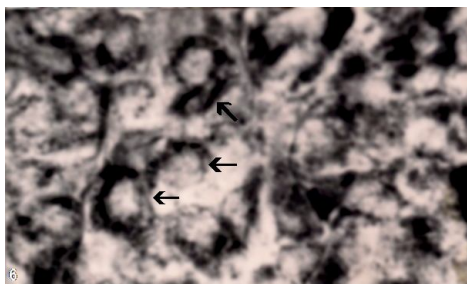


Figure 6. Corpuscles of Stannius of 21 days lead nitrate treated *Heteropneustes fossilis* exhibiting heavy accumulation of secretory granules (arrows) in AF-positive cells. Aldehyde fuchsin X 800.

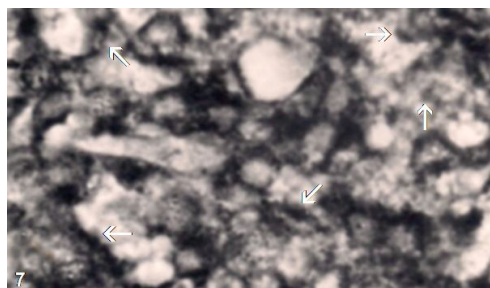


Figure 7. Corpuscles of Stannius of 28 days lead nitrate treated *Heteropneustes fossilis* exhibiting degeneration (arrows) of AF-positive cells. Aldehyde fuchsin X 800.

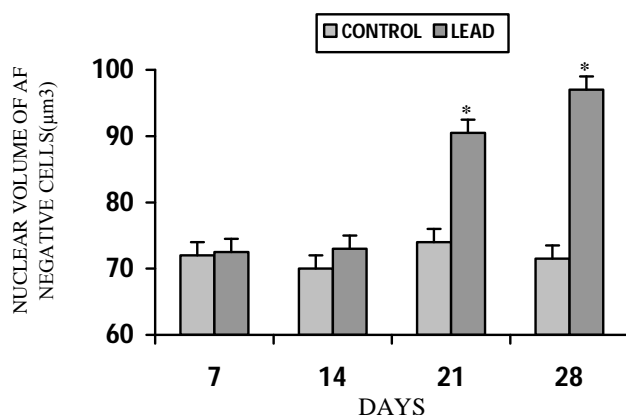


Figure 8. Nuclear volume of AF-negative cells of long-term lead nitrate exposed *Heteropneustes fossilis*. Values are mean \pm S.E. of six specimens. Asterisk indicates significant differences ($P < 0.05$) from control.

The hypocalcemia observed in lead exposed *H. fossilis* may be attributed to the impairment of either net electrolyte influx at the gill or renal function. Rogers *et al.* (10) have reported reduced calcium uptake in lead-exposed rainbow trout. Several investigators have reported degenerative changes in the gills of fishes after exposure to various pesticides (5, 6). Degeneration of gills may affect the ionic permeability and cause decreased ionic levels in the blood. Tubular necrosis may be the other possible reason for the hypocalcemia observed in lead exposed *H. fossilis*. Kidney degeneration has been reported by several workers after exposure of the fish to toxicants (29, 30). The increased urine excretion rate of Ca^{2+} has been observed in lead treated rainbow trout (31). The degeneration of kidney may lead to decreased reabsorption thus causing increased urinary loss of these ions. This increased loss of ions through the kidney may be the possible reason for the decreased concentration of calcium in lead treated *H. fossilis*. In the past, Koyama and Itazawa (32), Roch and Maly (33), Larsson *et al.* (13) and Haux and Larsson (34) have also

attributed degenerative changes in the renal tubules as one of the main causes of hypocalcemic responses in cadmium treated fishes. Patel *et al.* (31) have suggested that lead-induced ionoregulatory toxicity in rainbow trout, particularly the disturbance of Ca^{2+} homeostasis, is not exclusively a branchial phenomenon, but is in part a result of disruption of ionoregulatory mechanisms at the kidney.

The corpuscles of Stannius of lead treated fish exhibit increased granulation among the AF-positive cells and a decreased nuclear volume of these cells. The AF-positive cells have been associated with the release of stannioalcin which functions as a hypocalcemic hormone in teleosts (35-39). There exists no study regarding the effect of lead on the corpuscles of Stannius of fish. In the present study the observed increased granulation in the AF-positive cells may be attributed to the perpetual hypocalcemia induced by lead challenge to the fish *H. fossilis*. The accumulation of secretory granules noticed in the AF-positive cells of lead exposed fish derives support from the studies of earlier investigators who have also noticed similar response in toxicant exposed fish (18, 40-42). Accumulation of

secretory granules among mammalian calcitonin cells (which secrete a hypocalcemic hormone) has been reported in response to induced hypocalcemia (43-46).

CONCLUSION

The present findings suggest that exposure of the lead to stinging catfish *Heteropneustes fossilis* caused disturbances in the blood calcium content as well as inactivity of the corpuscles of Stannius. The environmental contamination with this metal can pose hazard for the fish populations and a serious problem for the aquaculture due to the disturbances in calcium regulation which is important for several vital physiological processes and reproduction.

ACKNOWLEDGMENT

The authors are thankful to colleagues who helped during the conduct of the experiment.

REFERENCES

1. Abedi Z, Khalesi M, Kohestan Eskandari S, Rahmani H. Comparison of Lethal Concentrations (LC50-96 H) of CdCl₂, CrCl₃, and Pb (NO₃)₂ in Common Carp (*Cyprinus carpio*) and Sutchi Catfish (*Pangasius Hypophthalmus*). Iranian Journal of Toxicology. 2012;6(18):672-80.
2. Has-Schön E, Bogut I, Strelec I. Heavy metal profile in five fish species included in human diet, domiciled in the end flow of River Neretva (Croatia). Archives of environmental contamination and toxicology. 2006;50(4):545-51.
3. Spokas EG, Bernd W, Smith H, Kemp FW, Bogden JD. Tissue lead concentration during chronic exposure of *Pimephales promelas* (fathead minnow) to lead nitrate in aquarium water. Environmental science & technology. 2006;40(21):6852-8.
4. Ates B, Orun I, Talas ZS, Durmaz G, Yilmaz I. Effects of sodium selenite on some biochemical and hematological parameters of rainbow trout (*Oncorhynchus mykiss* Walbaum, 1792) exposed to Pb²⁺ and Cu²⁺. Fish physiology and biochemistry. 2008;34(1):53-9.
5. Adeyemo OK. Histological alterations observed in the gills and ovaries of *Clarias gariepinus* exposed to environmentally relevant lead concentrations. Journal of environmental health. 2008;70(9):48-51.
6. Pandey S, Parvez S, Ansari RA, Ali M, Kaur M, Hayat F, et al. Effects of exposure to multiple trace metals on biochemical, histological and ultrastructural features of gills of a freshwater fish, *Channa punctata* Bloch. Chemico-biological interactions. 2008;174(3):183-92.
7. Hilal AK, Malabika Sikdar-Bar, Kamlesh B, Adil Abdullah Wani, Pervaiz Ahmed P. Lead Nitrate Induced Histopathological Changes in the Gills of the African *Clarias batrachus*. Journal Appl Sciences Res. 2011; 7(7): 1081-6.
8. Mobarak YMS, Sharaf MM. Lead acetate-induced histopathological changes in the gills and digestive system of silver sailfin molly (*Poecilia latipinna*). Int J Zool Res. 2011;7:1-18.
9. Sirimongkolvorakul S, Tansatit T, Preyavichyapugdee N, Kosai P, Jiraungkoorskul K, Jiraungkoorskul W. Efficiency of *Moringa oleifera* dietary supplement reducing lead toxicity in *Puntius altus*. Journal Medicinal Plants Res. 2012; 6(2): 187-94.
10. Rogers J, Richards J, Wood C. Ionoregulatory disruption as the acute toxic mechanism for lead in the rainbow trout (*Oncorhynchus mykiss*). Aquatic toxicology. 2003;64(2):215-34.
11. Singh N, Das V, Singh S. Effect of aldrin on carbohydrate, protein, and ionic metabolism of a freshwater catfish, *Heteropneustes fossilis*. Bulletin of environmental contamination and toxicology. 1996;57(2):204-10.
12. Srivastava S, Singh N, Srivastava AK, Sinha R. Acute toxicity of malachite green and its effects on certain blood parameters of a catfish, *Heteropneustes fossilis*. Aquatic toxicology. 1995;31(3):241-7.
13. Larsson Å, Bengtsson BE, Haux C. Disturbed ion balance in flounder, *Platichthys flesus* L. exposed to sublethal levels of cadmium. Aquatic toxicology. 1981;1(1):19-35.

14. Giles MA. Electrolyte and water balance in plasma and urine of rainbow trout (*Salmo gairdneri*) during chronic exposure to cadmium. *Canadian Journal of Fisheries and Aquatic Sciences*. 1984;41(11):1678-85.
15. Pratap H, Fu H, Lock R, Wendelaar Bonga S. Effect of waterborne and dietary cadmium on plasma ions of the teleost *Oreochromis mossambicus* in relation to water calcium levels. *Archives of environmental contamination and toxicology*. 1989;18(4):568-75.
16. Singh N, Das V, Srivastava A. Formothion and propoxur induced ionic imbalance and skeletal deformity in a catfish, *Heteropneustes fossilis*. *Journal of Environmental Biology*. 1997;18(4):357-63.
17. Srivastav AK, Srivastava S, Srivastava A. Response of serum calcium and inorganic phosphate of freshwater catfish, *Heteropneustes fossilis*, to chlorpyrifos. *Bulletin of environmental contamination and toxicology*. 1997;58(6):915-21.
18. Srivastav AK, Srivastava SK, Mishra D, Srivastav SK. Deltamethrin-induced alterations in serum calcium and prolactin cells of a freshwater teleost, *Heteropneustes fossilis*. *Toxicological and Environ Chemistry*. 2010;92(10):1857-64.
19. Mishra D, Srivastav S, Srivastav S, Srivastav A. Plasma calcium and inorganic phosphate levels of a freshwater catfish *Heteropneustes fossilis* in response to cypermethrin treatment. *Journal of Ecophysiology and Occupational Health*. 2001;1(1):131-8.
20. Kumar A, Prasad M, Mishra D, Srivastav SK, Srivastav AK. Botanical pesticide, azadirachtin attenuates blood electrolytes of a freshwater catfish *Heteropneustes fossilis*. *Pesticide Biochemistry and Physiology*. 2011;99(2):170-3.
21. Prasad M, Kumar A, Mishra D, Srivastav SK, Srivastav AK. Alterations in blood electrolytes of a freshwater catfish *Heteropneustes fossilis* in response to treatment with a botanical pesticide, *Nerium indicum* leaf extract. *Fish physiology and biochemistry*. 2011;37(3):505-10.
22. Sastry K, Sharma S. The effect of endrin on the histopathological changes in the liver of *Channa punctatus*. *Bulletin of environmental contamination and toxicology*. 1978;20(1):674-7.
23. Bansal S, Verma S, Gupta A, Dalela R. Physiological dysfunction of the haemopoietic system in a fresh water teleost, *Labeo rohita*, following chronic chlordane exposure. Part I—Alterations in certain haematological parameters. *Bulletin of environmental contamination and toxicology*. 1979;22(1):666-73.
24. Sharma M, Goel K, Awasthi A, Tyagi S. Haematological and biochemical characteristics of *Heteropneustes fossilis* under the stress of Congo Red (diphenyl disazo binaphthionic acid). *Toxicology Letters*. 1982;14(3):237-41.
25. Suzuki N, Tabata MJ, Kambegawa A, Srivastav AK, Shimada A, Takeda H, et al. Tributyltin inhibits osteoblastic activity and disrupts calcium metabolism through an increase in plasma calcium and calcitonin levels in teleosts. *Life sciences*. 2006;78(21):2533-41.
26. Eisler R. US Bur Sport Fish, Wildl Tech Paper 17. In: Edwards RP, editors. *Pesticides and Ecology*. 1967. P. 213-51.
28. Haux C, Larsson Å. Effects of DDT on blood plasma electrolytes in the flounder, *Platichthys flesus* L, in hypotonic brackish water. *Ambio*. 1979:171-3.
29. Velisek J, Svobodova Z, Piackova V. Effects of acute exposure to bifenthrin on some haematological, biochemical and histopathological parameters of rainbow trout (*Oncorhynchus mykiss*). *Veterinarni Medicina*. 2009;54(3):131-7.
30. Srivastava SK, Tiwari PR, Srivastav AK. Effects of chlorpyrifos on the kidney of freshwater catfish, *Heteropneustes fossilis*. *Bulletin of environmental contamination and toxicology*. 1990;45(5):748-51.
31. Rabitto I, Alves Costa J, Silva de Assis H, Pelletier E, Akaishi F, Anjos A, et al. Effects of dietary Pb (II) and tributyltin on neotropical fish, *Hoplias malabaricus*: histopathological and biochemical findings. *Ecotoxicology and Environmental Safety*. 2005;60(2):147-56.
32. Patel M, Rogers JT, Pane EF, Wood CM. Renal responses to acute lead waterborne exposure in the freshwater rainbow trout

- (*Oncorhynchus mykiss*). Aquatic toxicology. 2006;80(4):362-71.
33. Koyama J, Itazawa Y. Effects of Oral Administration of Cadmium on Fish- I. Analytical Results of the Blood and Bones,(In Japanese). Bulletin of the Japanese Society of Scientific Fisheries. 1977;43(5): 523-6.
 34. Roch M, Maly E. Relationship of cadmium-induced hypocalcemia with mortality in rainbow trout (*Salmo gairdneri*) and the influence of temperature on toxicity. Journal of the Fisheries Board of Canada. 1979;36(11):1297-303.
 35. Haux C, Larsson Å. Long-term sublethal physiological effects on rainbow trout, *Salmo gairdneri*, during exposure to cadmium and after subsequent recovery. Aquatic toxicology. 1984;5(2):129-42.
 36. Bonga S. Effect of synthetic salmon calcitonin and low ambient calcium on plasma calcium, ultimobranchial cells, Stannius bodies, and prolactin cells in the teleost *Gasterosteus aculeatus*. General and comparative endocrinology. 1980;40(1):99-108.
 37. WendelaarBonga SE, Pang PKT. Stannius corpuscles. In: Pang PKT, Schreiberman MP, editors. Vertebrate Endocrinology: Fundamentals and Biomedical Implications. London: Academic Press;1986.p.436-64.
 38. Bonga SW, Pang P. Control of Calcium Regulating Hormones in the Vertebrates: Parathyroid Hormone. International Review of Cytology: A Survey of Cell Biology. 1991;128:139-213.
 39. Pang PK, Pang RK. Hormones and calcium regulation in *Fundulus heteroclitus*. American zoologist. 1986;26(1):225-34.
 40. Srivastav AK, Srivastav SP. Corpuscles of Stannius of *Clarias batrachus* in response to 1, 25 dihydroxyvitamin D3 administration. Zoological science. 1988;5(1):197-200.
 41. Srivastav AK, Srivastava S, Mishra D, Srivastav S, Suzuki N. Effects of deltamethrin on serum calcium and corpuscles of Stannius of freshwater catfish, *Heteropneustes fossilis*. Toxicological and Environ Chemistry. 2009;91(4):761-72.
 42. Mishra D, Tripathi S, Srivastav SK, Suzuki N, Srivastav AK. Corpuscles of Stannius of a teleost, *Heteropneustes fossilis* following intoxication with a pyrethroids (cypermethrin). North-Western Journal of Zoology. 2010;6(2):203-8.
 43. Rai R, Tripathi S, Diwakar M, Srivastav SK, SrivastavAjai K. Cadmium-induced changes in the corpuscles of Stannius of a freshwater teleost, *Heteropneustes fossilis*. Egyptian Journal Biology. 2010; 12: 74-80.
 44. G ittes RF, Toverud SU, Cooper CW. Effects of hypercalcemia and hypocalcemia on the thyrocalcitonin content of rat thyroid glands. Endocrinology. 1968;82(1):83-90.
 45. Leitz H, Donath K. Cytochemical evidence for the presence of hormonal peptides in thyroid C cells. In: Taylor S, editors. Calcitonin 1969. London: William Heinemann Medical Books Ltd.1970p.227-39.
 46. Biddulph DM, Maibenco HC. Response of hamster thyroid light cells to plasma calcium. The Anatomical Record. 1972;173(1):25-43.
 47. Swarup K, Tewari N, Srivastav AK. Response of calcitonin cells, parathyroid glands and bone to prolonged calcitonin administration in the Indian palm squirrel, *Funambulus pennanti*(Wroughton). Cells Tissues Organs. 1980;106(2):180-91.