

Protective Role of Royal Jelly in Oxymetholone-induced Oxidative Injury in Mouse Testis

Gholamreza Najafi¹, Vahid Nejati², Ali Shalizar Jalali^{*1}, Ensieh Zahmatkesh²

Received: 01.10.2013

Accepted: 30.11.2013

ABSTRACT

Background: An adverse effect of oxymetholone (OXM), an anabolic-androgenic steroid used as energetic medicine, is reproductive toxicity. Royal jelly (RJ) is an efficient antioxidant that has been used to treat reproductive problems. In this study, we investigated the effects of RJ on OXM-induced oxidative injuries in mouse testes.

Methods: Male mice were divided into four groups. Two groups of mice were administered OXM (5 mg/kg/day, p.o.) for 28 days. One of these groups received RJ (100 mg/kg/day, p.o.) concurrently. A vehicle-treated control group and a RJ control group were also included.

Results: The OXM-treated group showed a significant decrease in the serum testosterone concentration and spermatogenic activities, along with many histological alterations. OXM treatment also caused a significant decrease in catalase activity with an increase in lipid peroxidation in the mouse testes. The above-noted parameters were restored to near normal levels by RJ co-administration.

Conclusion: The results demonstrate that RJ protects against OXM-induced reproductive toxicities.

Keywords: Mouse, Oxymetholone, Royal Jelly, Testis.

IJT 2014; 1073-1080

INTRODUCTION

Worldwide, up to 20% of couples are infertile. Approximately 30-50% of human infertility is attributable to male infertility [1, 2]. Although hormonal causes of male infertility are well known, lack of sufficient knowledge about intracellular mechanisms leading to the production of important factors necessary for regulating spermatogenesis is the main reason behind the inability to diagnose and treat certain forms of idiopathic infertility [3]. Testis, the main organ of the male reproductive system, consists of two parts: the testis parenchyma and intercellular substances. The parenchyma is composed of long and coiled tubes called seminiferous tubules. As the seminiferous tubules comprise approximately 80% of the testicular mass, the morphological measurements of seminiferous tubules are important in the studies of testis tissue [4-7].

Anabolic-androgenic steroids (AASs) are used by a considerable proportion of the

community to enhance their physique and performance. More than one million of Americans use or have used AASs [8]. Oxymetholone (OXM) is an active nutritional 17 α -alkylated anabolic-androgenic steroid derived from testosterone [9]. Since OXM can stimulate erythropoiesis and increases erythropoietin production, it is used for the treatment of anemias caused by low red cell production [10]. In addition, this drug is currently applied to the treatment of myelotoxic anticancer drugs-induced myelofibrosis [9] and AIDS-associated wasting [11]. Despite its therapeutic significance, it has been reported that OXM causes hepatic and cardiac damages [12, 13] as well as reproductive toxicities in humans and experimental animals [14-16]. Also, AASs have been found to induce hypogonadotropic hypogonadism via negative feedback to the hypothalamus leading to testicular atrophy and impaired spermatogenesis [17, 18].

1. Department of Basic Sciences, Urmia University, Urmia, Iran.

2. Department of Biology, Urmia University, Urmia, Iran.

*Corresponding Author: E-mail: a.shalizar@urmia.ac.ir

Royal jelly (RJ), a secretion product of the hypopharyngeal and mandibular glands of nurse bees, is a mixture that contains many important compounds with biological activity such as free amino acids, proteins, sugars, fatty acids, minerals, and vitamins [19]. Due to its complex composition, RJ possesses numerous pharmacological properties including antioxidant, anti-inflammatory, antitumor, anti-allergic, antibiotic, hypotensive, neurotrophic, and immunomodulatory activities [20-23]. Furthermore, independent studies have indicated that RJ has positive effects on the reproductive system and fertility in humans and animals [24-27]. Hence, the present study was designed to investigate the probable protective effects of RJ on OXM-induced oxidative injuries in mouse testes.

MATERIALS AND METHODS

Animals

This study was carried out on healthy adult sexually mature male (9 weeks of age) mice weighing 30 ± 2 g. A total of 32 mice were obtained from the Animal House of Faculty of Science, Urmia University, Urmia, Iran. The animals were housed in filter-top polycarbonate cages in an air-conditioned room (temperature: 25 ± 2 °C, relative humidity: $50 \pm 10\%$, and 12 h light/12 h dark photoperiod) free from any sources of chemical contamination with free access to standard diet and water throughout the experimental period. The experimental protocol and procedures used in this study were approved by the Ethics committee of the Urmia University, Urmia, Iran for the care and use of laboratory animals.

Experimental design

After seven days of acclimation to the environment, the mice were randomly divided into four treatment groups of eight animals each ($n = 8$) and treated orally for 28 days as follows:

Group I (Control): received saline vehicle (0.1 ml/mice)

Group II (OXM): OXM (5 mg/kg)

Group III (RJ): royal jelly (100 mg/kg)

Group IV (OXM + RJ): royal jelly (100 mg/kg) + OXM (5 mg/kg).

Sampling

Animals were euthanized by CO₂ exposure in a special device following anesthesia with ketamine (75 mg/kg, IP) 24 hours after the last treatment. Blood was collected from atrium in routine biochemical test tubes without anticoagulant for serological analysis. The abdominal cavity was opened up through a midline abdominal incision and the testes were excised quickly. One half of the right and left testes were fixed in Bouin's fixative (0.2% picric acid/2% (V/V) formaldehyde in PBS) for histological evaluation and the other halves were kept frozen at -70 °C until they were homogenized for further biochemical studies.

Assessment of catalase activity

Catalase (CAT) activity in homogenized testicular tissue was determined according to Aebi (1984) [28]. Its activity was assayed by determining the rate of degradation of hydrogen peroxide at 240 nm in 10 mM of potassium phosphate buffer (pH 7.0). Extinction coefficient of 43.6 mM/cm was used for calculation. One unit is defined as 1 pmol of hydrogen peroxide consumed per minute, and the specific activity is reported as units/mg of protein.

Assessment of lipid peroxidation

Lipid peroxidation (LPO) was determined by the spectrophotometric TBA assay as previously described [29]. Malondialdehyde (MDA), formed as an end product of the peroxidation of lipids, reacts with thiobarbituric acid (TBA) to generate a colored product that can be measured optically at 532 nm. Results were expressed as $\mu\text{mol MDA/mg protein}$.

Testosterone assessment

Serum concentration of testosterone was measured by enzyme-linked immunosorbent assay (ELISA) as described in the instructions provided by manufacturer's kit (Demeditec Diagnostics GmbH, Germany).

Histological analysis

After fixation of testes, they were dehydrated through a gradual series of alcohol

and cleared in three changes of xylene before embedded in paraffin. Thin sections (5µm) perpendicular to the longest axis of the testis were cut using a microtome and stained with hematoxylin and eosin according to the standard method. Histological analysis was performed under light microscope in terms of the changes in different groups as compared to the control group.

Determination of histological parameters

For each testis, five vertical sections from the polar and the equatorial regions were sampled [30] and an unbiased numerical estimation of the following histological parameters was determined using a systematic random scheme.

Seminiferous tubules diameter (STsD) and interstitial tissue thickness (ITT): For measuring STsD and ITT, 200 round or nearly round cross-sections of seminiferous tubules were randomly analyzed in each mouse (one hundred per testis). Then, two perpendicular diameters of each cross-section of seminiferous tubules were measured using an ocular micrometer of light microscopy (Olympus Co., Germany) and their means were calculated. Also, ITT was measured in 4 equidistance of each cross-section of seminiferous tubules and their means were calculated [31].

Number of mononuclear immune cells (MNICs) in testicular tissue: The number of MNICs was determined by using the unbiased counting frame proposed by Gundersen (1977) [32].

Tubule differentiation index (TDI) and spermiation index (SPI): 200 cross-sections of seminiferous tubules were randomly analyzed in each mouse (one hundred per testis) for the calculation of TDI and SPI. TDI is the percentage of seminiferous tubules containing

at least three differentiated germ cells [33]. SPI is the percentage of seminiferous tubules with normal spermiation [34].

Sertoli cell index (SCI) and mitotic index (MI): Sixty seminiferous tubules per group were randomly examined for the calculation of SCI and MI. SCI is the ratio of the number of germ cells to the number of Sertoli cells identified by a characteristic nucleus and nucleolus in all seminiferous tubules [35]. MI, the number of round spermatids for each pachytene primary spermatocytes, was calculated for determination of cell loss percentage during cell division [36].

Statistical analysis

The results are expressed as the mean ± standard error of mean (S.E.M.). Differences between the groups were assessed by the analysis of variance (ANOVA) using SPSS software package for Windows. Statistical significance between groups was determined by Tukey's multiple comparison post hoc test and the P-values less than 0.05 were considered to be statistically significant.

RESULTS

Antioxidant status study

The effects of different treatments on CAT activity and MDA level in testis are depicted in Table 1. Treatment with OXM alone resulted in a significant decrease in CAT activity in testis tissue, whereas it caused a significant increase in MDA in the same tissue. Treatment with RJ in combination with OXM resulted in a significant improvement in these parameters in testis tissues compared to the OXM alone group (Table 1).

Table 1. Effect of oxymetholone and Royal jelly on the testis antioxidant status.

	Control	OXM	RJ	OXM+RJ
CAT (U/mg pt.)	51.6±0.6	23.1±0.2 ^a	53.4±0.5 ^b	32.3±0.3 ^{a,b}
MDA (µmol/mg pt.)	3.9±0.1	6.2±0.2 ^a	3.8±0.2 ^b	4.7±0.1 ^{a,b}

The values are expressed as mean ± S.E.M. (n = 8).

a Significant differences as compared with the control group at P <0.05

b Significant differences as compared with the OXM group at P <0.05

Testosterone level

Results of testosterone concentrations study (Figure 1) revealed that treatment with OXM alone caused a significant decrease in serum testosterone level as compared to the

control group. The administration of RJ along with OXM significantly restored serum testosterone level towards the control value (Figure 1).

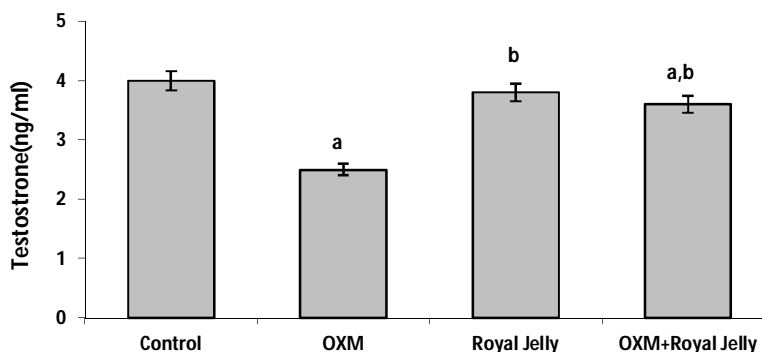


Figure 1. Effect of oxymetholone and Royal jelly on serum concentrations of testosterone.

The values are expressed as mean \pm S.E.M. (n=8).

a Significant differences as compared with the control group at P <0.05

b Significant differences as compared with the oxymetholone group at P <0.05

Histological parameters

As seen in Table 2, treatment of male mice with OXM caused a significant decrease in seminiferous tubules diameter (STsD), while interstitial tissue thickness (ITT) increased compared to that of control. Co-administration of RJ significantly attenuated the OXM-induced morphometric changes.

Data exist in Figure 2 revealed that infiltration of mononuclear immune cells (MNICs) in testicular tissue was significantly elevated by OXM treatment. However, this elevation in the number of MNICs was inhibited by concurrent treatment with RJ.

Moreover, OXM treatment induced the deletion of germ cells during spermatogenesis, which resulted in significant decreases in TDI and SCI (Table 3). Due to the germ cells deletion, SPI and MI were also greatly decreased in the OXM-treated mice (Table 3). RJ treatment significantly

prevented the OXM-induced germ cell loss from seminiferous tubules (Table 3).

Histopathologic findings

There were no marked histological alterations in testes of control (Figure 3a) and RJ-only (Figure 3b) groups, while drastic morphologic changes were observed in the testis of OXM-treated mice (Figure 3c). The seminiferous tubules of these animals showed severe hypocellularity and intraepithelial vacuolization and were displaced by some fibrinoid debris. Rupture, vacuolization, inflammatory cells infiltration, and interstitial space widening were also observed in intertubular connective tissue of testes following OXM treatment (Figure 3c). OXM-induced lesions in testicular tissue were greatly recovered by RJ co-administration, although partial disorganizations were observed in some seminiferous tubules epithelium (Figure 3d).

Table 2. Effect of oxymetholone and Royal jelly on histological parameters of testis.

	Control	OXM	RJ	OXM+RJ
STsD (μ m)	204.75 \pm 6.55	149.36 \pm 6.07 ^a	211.75 \pm 3.13 ^b	191.00 \pm 3.66 ^b
ITT (μ m)	48.50 \pm 5.02	155.83 \pm 9.27 ^a	51.08 \pm 5.71 ^b	45.75 \pm 2.45 ^b

STsD, seminiferous tubules diameter; ITT, interstitial tissue thickness.

The values are expressed as mean \pm S.E.M. (n = 8).

a Significant differences as compared with the control group at P <0.05

b Significant differences as compared with the OXM group at P <0.05

Table 3. Effect of oxymetholone and Royal jelly on spermatogenic activities.

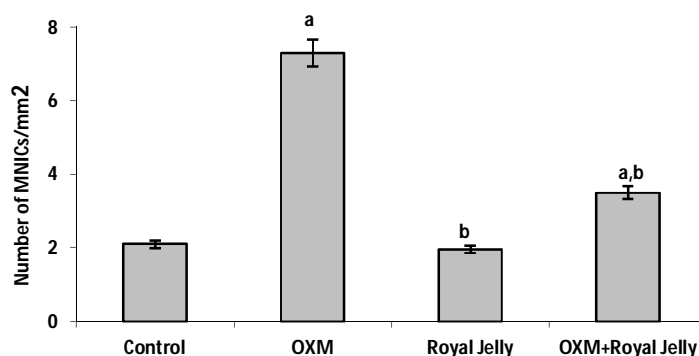
	Control	OXM	RJ	OXM+RJ
TDI (%)	65.83±4.40	41.66±2.20 ^a	70.33±1.45 ^b	87.50±3.01 ^{a,b}
SPI (%)	70.88±2.73	41.83±1.73 ^a	68.88±2.93 ^b	69.99±1.92 ^b
SCI (%)	63.73±0.66	47.16±3.10 ^a	62.73±1.44 ^b	56.30±1.80 ^b
MI (%)	68.61±8.28	38.88±1.46 ^a	75.55±9.82 ^b	77.77±8.01 ^b

TDI, tubule differentiation index; SPI, spermiation index; SCI, Sertoli cell index; MI, mitotic index.

The values are expressed as mean ± S.E.M. (n = 8).

a Significant differences as compared with the control group at P <0.05

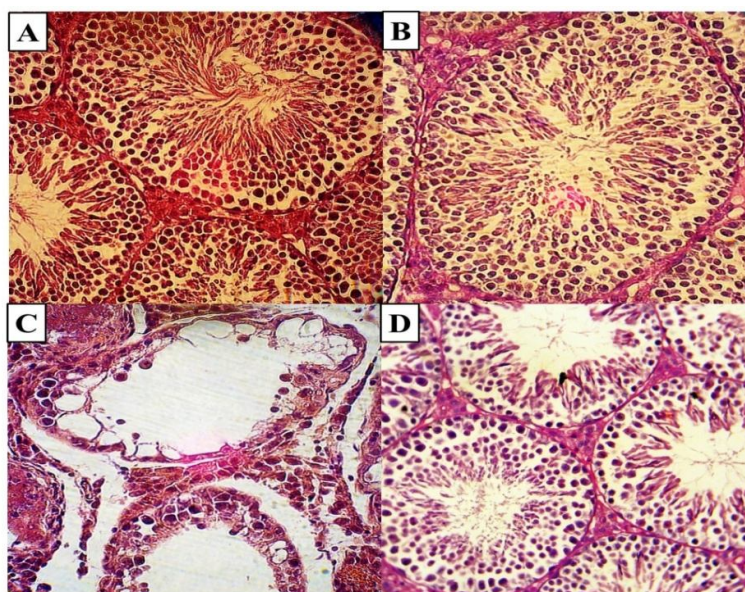
b Significant differences as compared with the OXM group at P <0.05

**Figure 2.** Effect of oxymetholone and Royal jelly on numbers of mononuclear immune cells (MNICs) in testicular tissue.

The values are expressed as mean ± S.E.M. (n = 8).

a Significant differences as compared with the control group at P <0.05

b Significant differences as compared with the oxymetholone group at P <0.05

**Figure 3.** Cross-sections of testes in mice treated with oxymetholone and/or royal jelly.

Testes from control (a) and RJ-treated (b) mice show intact seminiferous tubules with active spermatogenesis. However, a testis from an OXM-treated mouse (c) reveals germ cells deletion and impaired spermatogenesis. In the testis of a mouse treated with OXM and RJ, the seminiferous epithelium is less abnormal as compared with (c), although partial disorganizations appear in some seminiferous tubules epithelium.

Hematoxylin and eosin (×600)

DISCUSSION

Synthetic AASs do the same work as androgenic hormones do. Evidence exists that these compounds have profound effects on male endocrinological and reproductive systems [37]. It has been reported that AASs induce oligozoospermia and azoospermia (18) as well as sperm morphology impairment [16]. Previous study on male rats has also confirmed the potential of AASs for causing spermatogenic arrest [14]. Although the mechanism by which AASs cause reproductive toxicities is still under debate, impaired spermatogenesis is supposed to occur because of AASs-induced hypogonadotropic hypogonadism [17, 18].

Spermatogenesis is a complex process, where spermatogonia develop into highly differentiated spermatozoa through several strictly controlled steps [38] and histological parameters, such as STsD and ITT along with TDI, SPI, SCI and MI, can give information about the testicular damage degree as a consequence of germ cell death. In general, massive germ cell loss caused by reproductive toxicity is followed by considerable alterations in testicular histological parameters. As shown in the present study, depletion of seminiferous epithelium and the consequent changes in histological measurements caused by OXM were confirmed in our report.

In the present study, OXM treatment caused a marked reduction in serum testosterone level, confirming a previous report that AASs, especially 17α -alkylated steroids, induced marked depressions of serum testosterone and sex hormone-binding globulin by means of androgenic receptors occupation [39].

Sertoli cells (SCs) are the main somatic cells of testis which play a major role in cytoarchitectural organization of the seminiferous tubules and, more importantly, govern the differentiation of germ cells (GCs). The physical and functional supports of SCs are essential for GCs survival and development [1, 2]. Therefore, a potential explanation for the failure of spermiogenesis in the OXM-treated mice is disruption of testosterone-dependent junction of SCs with

GCs leading to their disorganization and separation.

MNICs infiltration in testicular tissue is an indicator of inflammation, a complex clinical condition that can negatively affect reproductive potential, which shows some alterations occur at the suspected testis. Hence, the elevation in MNICs infiltration observed in testicular tissue of OXM-treated animals might reflect the role of OXM in induction of inflammation.

To date, several reports have supported the fact that RJ has a predominant reproductive role in humans and animals. Recently, it has been revealed that oral administration of RJ counters "summer infertility" in male rabbits [24]. Furthermore, results of a study on 99 couples with asthenospermia-induced infertility have revealed that a simple and efficient way of treating this condition is the intravaginal administration of RJ and honey [25]. Additionally, it has been found that RJ has a potential positive effect on development of genital organ in male mice due to its highly efficient anti-oxidant properties [27].

In the present study, RJ co-administration provided effective protection against OXM-induced oxidative injuries in mouse testis. This reinforces the fact that RJ as a potent and safe antioxidant has beneficial effects against oxidative stress-related toxicities. The reason why RJ co-administration attenuated OXM-induced reproductive toxicity could be attributed to the fact that it contains spermatogenesis-stimulating substances such as vitamin C, vitamin E, and arginine [40]. Moreover, it has been demonstrated that RJ inhibits the production of pro-inflammatory cytokines by activated macrophages [41].

CONCLUSION

In sum, it can be concluded that RJ has a protective effect against OXM-induced reproductive toxicities through restoration of antioxidant defense system.

ACKNOWLEDGMENT

The authors gratefully acknowledge the financial assistance of Urmia University in performing this investigation.

REFERENCES

1. Matzuk MM, Lamb DJ. The biology of infertility: research advances and clinical challenges. *Nature medicine*. 2008;14(11):1197-213.
2. Ikawa M, Tergaonkar V, Ogura A, Ogonuki N, Inoue K, Verma IM. Restoration of spermatogenesis by lentiviral gene transfer: offspring from infertile mice. *Proceedings of the National Academy of Sciences*. 2002;99(11):7524-9.
3. Schaison G, Young J, Pholsena M, Nahoul K, Couzinet B. Failure of combined follicle-stimulating hormone-testosterone administration to initiate and/or maintain spermatogenesis in men with hypogonadotropic hypogonadism. *The Journal of clinical endocrinology and metabolism*. 1993;77(6):1545-9.
4. Hsieh M-L, Huang S-T, Huang H-C, Chen Y, Hsu Y-C. The reliability of ultrasonographic measurements for testicular volume assessment: comparison of three common formulas with true testicular volume. *Asian journal of andrology*. 2009;11(2).
5. Jiang Y-g, Peng T, Luo Y, Li M-c, Lin Y-h. Resveratrol reestablishes spermatogenesis after testicular injury in rats caused by 2, 5-hexanedione. *Chinese Medical Journal (English Edition)*. 2008;121(13):1204-9.
6. Prakash S, Prithiviraj E, Suresh S. Developmental changes of seminiferous tubule in prenatal, postnatal and adult testis of bonnet monkey (*Macaca radiata*). *Anatomia, histologia, embryologia*. 2008;37(1):19-23.
7. Sakamoto H, Yajima T, Nagata M, Okumura T, Suzuki K, Ogawa Y. Relationship between testicular size by ultrasonography and testicular function: measurement of testicular length, width, and depth in patients with infertility. *International journal of urology*. 2008;15(6):529-33.
8. Yesalis CE, Kennedy NJ, Kopstein AN, Bahrke MS. Anabolic-androgenic steroid use in the United States. *Jama*. 1993;270(10):1217-21.
9. Pavlatos AM, Fultz O, Monberg MJ, Vootkur A. Review of oxymetholone: a 17 α -alkylated anabolic-androgenic steroid. *Clinical therapeutics*. 2001;23(6):789-801.
10. Hosseinimehr SJ, Zakaryaee V, Froughizadeh M. Oral oxymetholone reduces mortality induced by gamma irradiation in mice through stimulation of hematopoietic cells. *Molecular and cellular biochemistry*. 2006;287(1-2):193-9.
11. Hengge UR, Stocks K, Wiehler H, Faulkner S, Esser S, Lorenz C, et al. Double-blind, randomized, placebo-controlled phase III trial of oxymetholone for the treatment of HIV wasting. *AIDS*. 2003;17(5):699-710.
12. Karila T, Karjalainen J, Mäntysaari M, Viitasalo M, Seppälä T. Anabolic androgenic steroids produce dose-dependent increase in left ventricular mass in power athletes, and this effect is potentiated by concomitant use of growth hormone. *International journal of sports medicine*. 2003;24(05):337-43.
13. Mooradian AD, Morley JE, Korenman SG. Biological actions of androgens. *Endocrine Reviews*. 1987;8(1):1-28.
14. Kind FA, Maqueo M, Dorfman RI. Influence of various steroids on testes and accessory sex organs in the rat. *Acta endocrinologica*. 1965;49(1):145-54.
15. Klaiber EL, Henzl MR, Lloyd CW, Segre EJ. Corpus Luteum-Inhibiting Action of Oxymetholone. *The Journal of Clinical Endocrinology & Metabolism*. 1973;36(1):142-7.
16. Torres-Calleja J, Gonzalez-Unzaga M, DeCelis-Carrillo R, Calzada-Sanchez L, Pedron N. Effect of androgenic anabolic steroids on sperm quality and serum hormone levels in adult male bodybuilders. *Life sciences*. 2001;68(15):1769-74.
17. Jarow JP, Lipshultz LI. Anabolic steroid-induced hypogonadotropic hypogonadism. *The American journal of sports medicine*. 1990;18(4):429-31.
18. Schürmeyer T, Belkien L, Knuth U, Nieschlag E. Reversible azoospermia induced by the anabolic steroid 19-nortestosterone. *The lancet*. 1984;323(8374):417-20.
19. Karaali A, Meydanoglu F, Eke D. Studies on composition, freeze-drying and storage of Turkish royal jelly. *Journal of apicultural research*. 1988; 27: 182-5.
20. Guo H, Ekusa A, Iwai K, Yonekura M, Takahata Y, Morimatsu F. Royal jelly peptides inhibit lipid peroxidation in vitro and in vivo. *Journal of nutritional science and vitaminology*. 2008;54(3):191-5.
21. Hattori N, Nomoto H, Fukumitsu H, Mishima S, Furukawa S. Royal jelly and its unique fatty acid, 10-hydroxy-trans-2-decenoic acid, promote neurogenesis by neural stem/progenitor cells in vitro. *Biomedical research (Tokyo, Japan)*. 2007;28(5):261-6.
22. Fujiwara S, Imai J, Fujiwara M, Yaeshima T, Kawashima T, Kobayashi K. A potent antibacterial protein in royal jelly. Purification and determination of the primary structure of

- royalisin. *Journal of biological chemistry*. 1990;265(19):11333-7.
23. Šver L, Oršolić N, Tadić Z, Njari B, Valpotic I, Bašić I. A royal jelly as a new potential immunomodulator in rats and mice. *Comparative immunology, microbiology and infectious diseases*. 1996;19(1):31-8.
24. Elnagar SA. Royal jelly counteracts bucks' "summer infertility". *Animal reproduction science*. 2010;121(1):174-80.
25. Abdelhafiz AT, Muhamad JA. Midcycle pericoital intravaginal bee honey and royal jelly for male factor infertility. *International Journal of Gynecology & Obstetrics*. 2008;101(2):146-9.
26. Husein M, Haddad S. A new approach to enhance reproductive performance in sheep using royal jelly in comparison with equine chorionic gonadotropin. *Animal reproduction science*. 2006;93(1):24-33.
27. Kato A, Onodera M, Ishijima Y. Effect of royal jelly on development of genital organ in male mice. *Journal of the Tokyo Society of Veterinary and Zootechnical Science (Japan)*. 1988; 35: 1-4.
28. Aebi H. Catalase in vitro. *Methods Enzymol*. 1984;105:121-6.
29. Esterbauer H, Cheeseman KH. Determination of aldehydic lipid peroxidation products: malonaldehyde and 4-hydroxynonenal. *Methods in enzymology*. 1990;186:407-21.
30. Qin D, Lung MA. Morph metric study on Leydig cells in capsulectomized testis of rats. *Asian J Androl*. 2002; 4: 49-53.
31. Vendramini V, Sasso-Cerri E, Miraglia SM. Amifostine reduces the seminiferous epithelium damage in doxorubicin-treated prepubertal rats without improving the fertility status. *Reproductive Biology and Endocrinology*. 2010;8(1):3.
32. Gundersen HJG. Notes on the estimation of the numerical density of arbitrary profiles: the edge effect. *Journal of microscopy*. 1977;111(2):219-23.
33. Porter KL, Shetty G, Meistrich ML. Testicular edema is associated with spermatogonial arrest in irradiated rats. *Endocrinology*. 2006;147(3):1297-305.
34. Rezvanfar M, Sadrkhanlou R, Ahmadi A, Shojaei-Sadee H, Mohammadirad A, Salehnia A, et al. Protection of cyclophosphamide-induced toxicity in reproductive tract histology, sperm characteristics, and DNA damage by an herbal source; evidence for role of free-radical toxic stress. *Human & experimental toxicology*. 2008;27(12):901-10.
35. Kang J-K, Lee Y-J, No K-O, Jung E-Y, Sung J-H, Kim Y-B, et al. Ginseng intestinal metabolite-I (GIM-I) reduces doxorubicin toxicity in the mouse testis. *Reproductive Toxicology*. 2002;16(3):291-8.
36. Kheradmand A, Dezfoulian O, Tarrahi MJ. Ghrelin attenuates heat-induced degenerative effects in the rat testis. *Regulatory peptides*. 2011;167(1):97-104.
37. Ruokonen A, Alen M, Bolton N, Vihko R. Response of serum testosterone and its precursor steroids, SHBG and CBG to anabolic steroid and testosterone self-administration in man. *Journal of steroid biochemistry*. 1985;23(1):33-8.
38. Tanaka SS, Toyooka Y, Akasu R, Katoh-Fukui Y, Nakahara Y, Suzuki R, et al. The mouse homolog of *Drosophila Vasa* is required for the development of male germ cells. *Genes & development*. 2000;14(7):841-53.
39. Sader MA, Griffiths KA, McCredie RJ, Handelsman DJ, Celermajer DS. Androgenic anabolic steroids and arterial structure and function in male bodybuilders. *Journal of the American College of Cardiology*. 2001;37(1):224-30.
40. Hassan A. Effect of royal jelly on sexual efficiency in adult male rats. *Iraqi Journal of Veterinary Sciences*. 2009;23: 155-60.
41. Kohno K, Okamoto I, Sano O, Arai N, Iwaki K, Ikeda M, et al. Royal jelly inhibits the production of proinflammatory cytokines by activated macrophages. *Bioscience, biotechnology, and biochemistry*. 2004;68(1):138-45.