

Original Article**Attenuation of Biochemical, Haematological and Histological Indices of Alloxan Toxicity in Male Rats by Aqueous Extract of *Fadogia agrestis*(Schweinf. Ex Hiern) Stems**

Musa Toyin Yakubu^{*1}, Olalekan Bukunmi Ogunro¹, Oluwayemisi Beatrice Ojewuyi²

Received: 19.01.2015

Accepted: 18.02.2015

ABSTRACT

Background: The effects of aqueous extract of *Fadogia agrestis* stem at the doses of 18, 36, and 72 mg/kg body weight on alloxan-induced toxicity was investigated in Wistar rats.

Methods: In total, 35 rats of both sexes (132.80±7.22g) were randomized into five groups (A-E): animals in group A received 0.5 ml of distilled water orally on daily basis for 15 days while the alloxanized rats in groups B, C, D and E also received orally 0.5 ml of distilled water and same volume of the extract corresponding to 18, 36, and 72 mg/kg body weight, respectively after which levels of some biomolecules were determined and histological changes evaluated.

Results: Administration of alloxan significantly ($P<0.05$) increased blood urea nitrogen (BUN)/creatinine ratio, levels of serum total and conjugated bilirubin, uric acid, Na⁺, K⁺, Ca²⁺ and Cl⁻ as well as activities of alkaline phosphatase (ALP), aspartate aminotransferase (AST), and alanine aminotransferase (ALT) in the serum whereas activities of ALP, AST and ALT in the liver and kidney, erythrocytes and leucocytes indices, total protein, globulin and PO4²⁻ levels as well as albumin/globulin ratio decreased ($P<0.05$) significantly. Alloxan also caused severe necrosis of the tubular epithelial cells in the nephrons and degeneration of the hepatocytes. Although all the doses of the plant extract significantly mitigated these changes, the reversals at 72 mg/kg body weight of the extract compared well ($P>0.05$) with their respective non-alloxanized distilled water treated control animals in 78% of the parameters investigated.

Conclusion: Overall, the aqueous extract of *F. agrestis* stem attenuated the alloxan treatment related biochemical, haematological and histological changes in the rats with the 72 mg/kg body weight achieving total reversal in 18 out of the 23 parameters investigated.

Keywords: Alloxan, Diabetes Mellitus, *Fadogia agrestis*, Mitigation, Reversal.

IJT 2015; 1392-1400

INTRODUCTION

Alloxan is a hydrophilic and unstable chemical compound with a shape similar to that of glucose that allows its transportation within the cells of animals. It is a widely used diabetogenic agent in experimental animals like rats, dogs and rabbits to induce Type I diabetes [1,2]. It is a toxic glucose analogues that preferentially accumulate in pancreatic beta cells via the Glucose Transporter 2. The cytotoxic action of alloxan involves oxidation of essential sulphhydryl (-SH) group, inhibition of glucokinase enzymes, generation of free radicals and disturbance of intracellular calcium homeostasis [1,2]. The presence of intracellular thiols, especially

glutathione, generates reactive oxygen species (ROS) in a cyclic redox reaction with its reduction product, dialuric acid [3]. Autoxidation of dialuric acid produces superoxide radicals, hydrogen peroxide and, in a final iron-catalysed reaction step, hydroxyl radicals [4]. These free radicals are ultimately responsible for the death of the beta cells, which have a particularly low antioxidant defence capacity, and the ensuing state of insulin-dependent 'alloxan diabetes'. These radicals may also adversely affect the normal functioning of the system of experimental animals. Lenzen [5] reported that protection against the cytotoxic action of alloxan and dialuric acid can be provided only by a combina-

1. Department of Biochemistry, University of Ilorin, P.M.B 1515, Ilorin, Nigeria.

2. Department of Biological Sciences, College of Natural Sciences, Al-Hikmah University, Ilorin, Nigeria.

* Corresponding Author: E-mail: tomuyak@yahoo.com

tion of superoxide dismutase and catalase, which completely prevents redox cycling between alloxan and dialuric acid, and thus the generation of ROS species.

Studies have also been reported in open scientific literature on altered biochemical parameters of the liver and kidney functions, haematological parameters and histoarchitectural changes following the administration of alloxan and or extracts of medicinal plants [6-8]. This has therefore necessitated more researches on the effects of medicinal plants on alloxan-induced toxicity in animals.

Fadogia agrestis, locally known in English as black aphrodisiac and by the Hausa tribe of Nigeria as Murshikan Dutse, belong to the Rubiaceae family. It is an erect shrub that is 1-3 feet tall, tomentellous stems with yellow leaves. This plant has been reported to contain saponins, alkaloids, flavonoids, and anthraquinones [9]. The aphrodisiac, antimicrobial and antidiabetic activities of the *F. agrestis* stem have been scientifically evaluated and reported [9-11]. Although, the aqueous extract of *F. agrestis* stem have been reportedly evaluated for its anti-diabetic activity at 18, 36 and 72 mg/kg body weight in alloxan-induced diabetic using serum blood glucose, urea, creatinine, lipids and hexokinase activity [11], there is dearth of information on the possibility of protective or restorative (attenuation/amelioration) activities of *F. agrestis* stem on alloxan-induced toxicity using biochemical, haematological and histological indices.

Therefore, the present study was undertaken to provide information on the restorative effects of aqueous extract of *F. agrestis* stem on alloxan-induced toxicity in rats using biochemical indices of the liver and kidney functions, haematological parameters, liver and kidney histology. This investigation is a further study on that previously reported by Yakubu and Ogunro [11].

MATERIALS AND METHODS

Plant Material

The plant sample was bought from the herb sellers at Kulende Market, Ilorin, Nigeria. It was authenticated at the Department of Horticul-

ture and Landscape Technology, Federal School of Forestry, Jos, Nigeria. A voucher specimen (2:108) was deposited at the Departmental Herbarium.

Experimental Animals

Thirty five albino rats of both sexes (132.80±7.22g) obtained from the Animal Breeding Unit of the Department of Biochemistry, University of Ilorin, Ilorin, Nigeria, were allowed to acclimatize for 14 days in aluminium cages placed in well-ventilated housing conditions (temperature: 22±3°C; about 12 h light-dark cycle; humidity: 45-50 %). The animals were maintained under this condition throughout the experimental period. They were also allowed free access to rat pellets (Premier Feed Mill Co. Ltd., Ibadan, Nigeria) and tap water.

Chemicals, Assay Kits and Haematological Analyser

Alloxan monohydrate used was a product of Sigma Chemical Company, St. Louis, Mo, USA. The assay kits for total protein, albumin, urea, uric acid, creatinine, total and conjugated bilirubin, alkaline phosphatase (ALP), aspartate aminotransferase (AST) and alanine aminotransferase (ALT) were products of Randox Laboratories Ltd., Co-Antrim, UK, while that of chloride ion was a product of Quimica Clinical Aplicada Ltd, Amposta, Spain. The assay kits for sodium, potassium, calcium and phosphate ions were products of Agappe Diagnostics Ltd, Kerala, India. The automated haematological analyzer SYSMEX KX21 was a product of SYSMEX Corporation, Harrier, Japan.

Preparation of the Extract

The aqueous extract of *F. agrestis* stem was prepared as previously described by Yakubu and Ogunro [11].

Animal Grouping and Administration of Alloxan and Extract

A total of 35 rats of both sexes were assigned into five groups, A-E, of seven rats each such that animals in group A received 0.5 ml of distilled while those in groups B-E were intraperitoneally injected with 1 ml corresponding to

150 mg/kg body weight of alloxan monohydrate in sterile physiological saline. After 48 hours of alloxan injection, the alloxan treated animals in groups B, C, D and E were administered 0.5 ml of distilled water and same volume corresponding to 18, 36 and 72 mg/kg body weight of *F. agrestis* stem extract respectively. The distilled water and the extract were administered orally, once daily, for 15 days between 08:00-09:00 hours. The animals were allowed free access to rat pellets (Premier Feed Mill Co. Ltd., Ibadan, Nigeria) and contaminant free tap water. The approval to carry out this study was obtained from the Ethical Committee on the Use and Care of animals of the Department of Biochemistry, University of Ilorin, Nigeria. The animals were also handled according to the guidelines of NRC [12].

Preparation of Serum and Tissue Supernatants

Twenty four hours after the last doses of the extract and distilled water, the animals were anaesthetized using diethyl ether. The unconscious rats were quickly removed from the jar after which the neck area was cleared of fur. The jugular veins were cut and an aliquot of the blood was collected into tubes containing heparin for haematological analysis while about 5 ml of the blood collected into plain tubes were left to clot for 30 minutes at room temperature and centrifuged at 1282 x g for 5 minutes. The resulting serum was collected into sample bottles with the aid of Pasteur pipette, stored frozen and used within 24 hours of preparation for the biochemical analyses. The animals were thereafter dissected, the liver and kidney were excised and blotted in blotting paper. The kidneys were also decapsulated after which these organs were separately weighed and homogenized in ice-cold 0.25M sucrose solution (1:5 w/v). The homogenates were centrifuged at 1789 x g for 10 minutes to obtain the supernatant, which was then used within 24 hours for the biochemical analyses.

Determination of Biochemical Parameters

Biochemical parameters evaluated in the present study were as described for globulin, calcium, sodium, potassium and uric acid [13],

alanine aminotransferase and aspartate aminotransferase [14], alkaline phosphatase [15], total protein [16], total and conjugated bilirubin [17], chloride ion [18] and phosphate ions [19]. Others include urea [20], creatinine [21] and albumin [22]. The albumin:globulin and blood urea:creatinine were computed from their respective determinations.

Determination of Haematological Parameters

The haematological parameters (red blood cells (RBC), mean corpuscular volume (MCV), mean corpuscular haemoglobin (MCH), mean corpuscular haemoglobin concentration (MCHC), white blood cells (WBC), neutrophils, eosinophils, basophils, monocytes, lymphocytes and platelets were determined using automated haematologic analyser.

Histopathological Examination

Histopathological examination of the liver and kidney was done using the procedure described by Drury and Wallington [23] and Krause [24]. The photomicrographs were observed using Olympus microscope connected to a system that used Presto Image folio software and were captured at x400.

Statistical Analysis

Data from this study were expressed as qualitative for the histopathological studies and quantitative for the biochemical and haematological studies. The quantitative data were expressed as mean \pm SEM of seven determinations and statistical analysis was done using Duncan Multiple Range Test at 5% level of confidence ($P < 0.05$). All the analyses were performed using SPSS version 20.0 software (SPSS Inc., Chicago, IL, USA).

RESULTS

Administration of alloxan significantly ($P < 0.05$) decreased the activities of ALP, AST and ALT in the liver and kidney, levels of total protein, globulin, phosphate ions and computed albumin/globulin ratio in the serum of the animals when compared with the non-alloxanized distilled water treated control animals (Table 1). Furthermore, the same alloxan administration

significantly ($P < 0.05$) increased the activities of ALP, AST and ALT in the serum of the animals, serum concentrations of total and conjugated bilirubin, uric acid, sodium, potassium, chloride and calcium ions as well as the computed blood urea nitrogen/creatinine ratio (Table 1). The administration of all the doses of the extract significantly ($P < 0.05$) mitigated and in some cases reversed the trends of these alloxan treatment related changes in the biochemical parameters towards the control values (Table 1). For instance, while all the doses significantly mitigated against the changes in the levels of these parameters by alloxan, the 72 mg/kg body weight of the extract completely reversed and restored ($P > 0.05$) the activities of ALP in the liver, kidney and serum, ASP in the liver and kidney, ALT in the liver and kidney, the levels of serum total protein, uric acid, globulin, sodium, potassium, calcium and phosphate ions as well as computed blood urea nitrogen/creatinine and albumin/globulin ratios corresponding to 78% reversal of the liver and kidney function indices of the rats investigated in the present study (Table 1).

The significantly ($P < 0.05$) reduced levels of red blood cells, mean corpuscular volume, mean corpuscular haemoglobin, mean corpuscular haemoglobin concentration, neutrophils, monocytes, lymphocytes, eosinophils, basophils and platelets following the administration of alloxan were dose dependently and significantly ($P < 0.05$) elevated by the extract (Table 2). The elevation produced by the extract on all the haematological parameters except the red blood cells were not significantly ($P > 0.05$) higher than those of the non-alloxanized rats treated with distilled water. Furthermore, the administration of the 72 mg/kg body weight of the extract produced levels of lymphocytes, white blood cells, mean corpuscular haemoglobin concentration and mean corpuscular haemoglobin that compared favourably ($P > 0.05$) with those of the non-alloxanized distilled water treated rats (Table 2).

Conventional architecture of the liver and kidney at the cellular level was displayed by the non-alloxanized distilled water treated control rats (Figures 1 and 6 respectively). Administration of alloxan produced severe liver architectur-

al distortion with hepatocellular degeneration, periportal necrosis, congestion of central vein with inflammatory cell infiltration (Figure 2) and severe architectural distortion in the kidney (Figure 7). However, treatment of alloxanized animals with various doses of the extract showed moderate hepatocellular (Figures 3-5) and normal kidney histoarchitecture (Figures 8-10).

DISCUSSION

Numerous animal models have been developed for the past few decades for studying diabetes mellitus on which the efficacy of chemical compounds including plant extracts and its products as anti-diabetic agent(s) can be evaluated. Several procedures that can be used to induce diabetes in animals include chemicals like alloxan and streptozotocin, surgical and genetic manipulations [25]. One of the most potent and widely used diabetogenic agent is alloxan.

Alloxan, a chemical agent that induces Type 1 diabetes in experimental animals, is a urea derivative that causes selective necrosis of the β -cells of the pancreas [26]. Apart from necrotic effect on the pancreas, it also adversely affect other organs of the experimental animals leading to alterations in the haematological parameters and biochemical parameters of organ function that eventually culminate into hampering the normal function indices of these organs. The histoarchitecture of these organs are also not spared during alloxan toxicity in animals. Therefore, the need to document agents/compounds including medicinal plants that can ameliorate, attenuate or mitigate these alloxan toxicity cannot be overemphasized.

The use of plants for various purposes such as providing shelter, as food, source of income, and in folkloric management of diseases dates back to millennia. In addition, plants are now been explored to mitigate/attenuate and/or reverse chemical compound-induced toxicity in animals.

In the present study, *F. agrestis* stem treatment related attenuation of alloxan-induced toxicity was assessed in biological system using indices such as biochemical, haematological and histological changes.

Table 1. Selected liver and kidney function indices of alloxanized rats treated with aqueous extract of *Fadogia agrestis* stem.

Parameters	Alloxan +				
	<i>F. agrestis</i> (mg/kg body weight)				
	Control	Distilled wa- ter	18	36	72
Liver ALP	140.3±10 ^a	86.7±7 ^b	165.0±9 ^c	160.7±12 ^c	141.0±6 ^a
Serum ALP	23.0±0.4 ^a	50.5±0.3 ^b	55.5±0.3 ^c	34.3±0.6 ^d	22.0±0.4 ^a
Liver AST	234.0±6 ^a	128.7±9 ^b	256.0±10 ^c	245.7±17 ^c	234.3±9 ^a
Serum AST	3.8±0.5 ^a	12.5±0.3 ^c	7.3±0.3 ^d	5.9±0.3 ^c	4.5±0.6 ^b
Liver ALT	172.0±9 ^a	92.3±0.9 ^b	196.7±9 ^c	188.0±12 ^c	175.3±7 ^a
Serum ALT	1.1±0.7 ^a	15.8±0.3 ^c	7.2±0.5 ^d	5.80±0.3 ^c	2.9±0.9 ^b
Total Protein (g/L)	145.5±5 ^a	113.3±5 ^b	138.0±4 ^c	140.3±11 ^a	144.8±7 ^a
Globulin (g/L)	107.3±5 ^a	93.6±5 ^d	105.0±4 ^c	106.7±5 ^b	110.5±7 ^a
Total Bilirubin (µmol/L)	13.8±0.6 ^a	35.3±0.3 ^c	32.0±0.4 ^d	25.7±0.4 ^c	23.0±0.3 ^b
Conjugated Bilirubin (µmol/L)	4.7±0.1 ^a	13.3±0.2 ^d	10.2±0.1 ^c	9.6±0.2 ^b	9.1±0.1 ^b
Albumin: Globulin ratio	1:14	1:8	1:9	1:12	1:14
Kidney ALP	175.3±4 ^a	105.5±3 ^b	185.5±3 ^c	184.3±6 ^c	176.0±4 ^a
Kidney ALT	104.7±8 ^a	299.3±13 ^b	201.3±13 ^c	190.0±8 ^d	106.7±9 ^a
Kidney AST	130.3±7 ^a	224.0±12 ^d	185.3±3 ^c	179.0±9 ^b	129.0±10 ^a
Uric acid (mmol/L)	0.3±0.01 ^a	1.2±0.01 ^d	0.9±0.01 ^c	0.8±0.01 ^b	0.3±0.01 ^a
Serum Na ⁺ (mmol/L)	133.7±6 ^a	148.5±7 ^c	140.3±5 ^b	139.3±6 ^b	134.0±4 ^a
Serum K ⁺ (mmol/L)	3.2±0.01 ^a	5.0±0.01 ^d	4.6±0.05 ^c	4.10±0.2 ^b	3.2±0.01 ^a
Serum Cl ⁻ (mmol/L)	98.5±2 ^a	106.8±5 ^b	105.8±6 ^b	105.0±4 ^b	105.3±7 ^b
Serum Ca ²⁺ (mmol/L)	2.6±0.01 ^a	5.1±0.05 ^b	5.0±0.05 ^b	3.5±0.01 ^c	2.4±0.01 ^a
Serum PO ₄ ²⁻ (mmol/L)	1.1±0.01 ^a	0.6±0.01 ^d	0.4±0.01 ^c	0.7±0.01 ^b	1.0±0.01 ^a
Blood urea nitrogen (BUN): creatinine ratio	1:3	1:5	1:4	1:3	1:3

Data are mean ± SEM of seven determinations. Test values carrying superscripts different from the control for each parameter are significantly different ($P < 0.05$).

Table 2. Haematological parameters of alloxanized rats administered aqueous extract of *Fadogia agrestis* stem.

Parameters	Alloxan +				
	<i>F. agrestis</i> (mg/kg body weight)				
	Control	Distilled water	18	36	72
RBC ($\times 10^{12} L^{-1}$)	3.0±0.1 ^a	2.3±0.1 ^d	4.6±0.3 ^c	5.9±0.1 ^b	6.0±0.11 ^b
MCV (fL)	64.5±8 ^a	41.8±6 ^c	52.3±3 ^d	55.3±5 ^c	59.7±4 ^b
MCH (pg)	17.9±0.2 ^a	6.9±0.2 ^d	11.2±0.8 ^c	13.5±0.2 ^b	17.0±0.3 ^a
MCHC (g/dL)	27.7±0.2 ^a	13.2±0.9 ^d	21.1±0.1 ^c	23.1±0.6 ^b	26.9±0.1 ^a
WBC ($\times 10^3 \mu L^{-1}$)	17.2±0.7 ^a	6.9±0.2 ^d	9.1±0.6 ^c	14.7±0.3 ^b	17.5±0.3 ^a
Neutrophil (%)	51.6±0.4 ^a	23.1±0.8 ^c	36.9±0.4 ^d	43.8±0.5 ^c	45.9±0.4 ^b
Monocytes (%)	9.2±0.02 ^a	0.4±0.03 ^c	1.0±0.04 ^d	1.9±0.02 ^c	2.2±0.01 ^b
Lymphocytes (%)	48.2±0.4 ^a	34.9±0.3 ^c	45.9±0.9 ^b	47.8±0.4 ^b	48.8±0.2 ^a
Eosinophil (%)	3.9±0.01 ^a	1.1±0.01 ^d	1.1±0.01 ^d	1.2±0.04 ^c	2.0±0.02 ^b
Basophil (%)	1.5±0.01 ^a	0.7±0.01 ^d	0.8±0.01 ^{cd}	0.9±0.01 ^b	0.9±0.02 ^b
Platelets ($\times 10^3 \mu L$)	836.8±13 ^a	567.0±13 ^c	799.3±12 ^d	800.9±14 ^c	803.6±12 ^b

Data are mean ± SEM of seven determinations. Test values carrying superscripts different from the control for each parameter are significantly different ($P < 0.05$).

RBC: Red Blood Cells; **MCV:** Mean Corpuscular Volume; **MCH:** Mean Corpuscular Haemoglobin; **MCHC:** Mean Corpuscular Haemoglobin Concentration; **WBC:** White Blood Cells

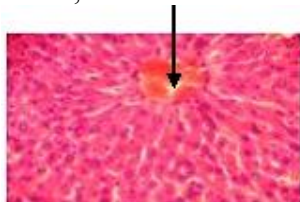


Figure 1. Cross section of the liver of non-alloxanized rat administered distilled water (x400; H&E).

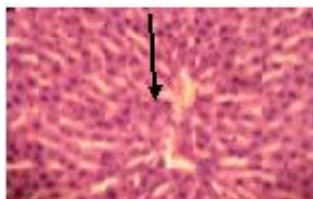


Figure 2. Cross section of the liver of alloxanized rat administered distilled water (x400; H&E).

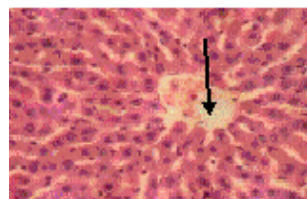


Figure 3. Cross section of the liver of alloxanized rat administered 18 mg/kg body weight of extract (x400; H&E).

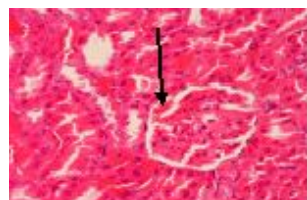


Figure 4. Cross section of the liver of alloxanized rat administered 36 mg/kg body weight of extract (x400; H&E).

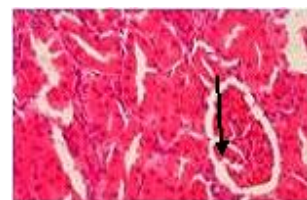

Figure 5. Cross section of the liver of alloxanized rat administered 72 mg/kg body weight of extract (x400; H&E).

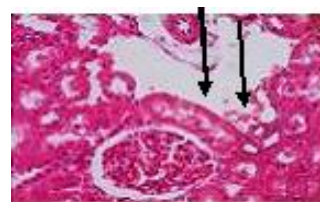

Figure 6. Cross section of the kidney of non-alloxanized rat administered distilled water (x400; H&E).

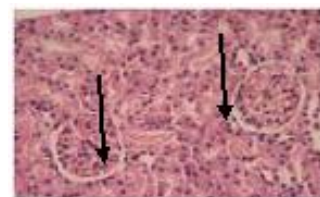


Figure 7. Cross section of the kidney of alloxanized rat administered distilled water (x400; H&E).

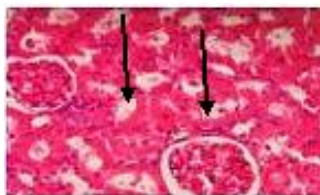

Figure 8. Cross section of the kidney of alloxanized rat administered 18 mg/kg body weight of extract (x400; H&E).

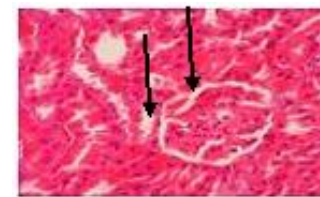

Figure 9. Cross section of the kidney of alloxanized rat administered 36 mg/kg body weight of extract (x400; H&E).

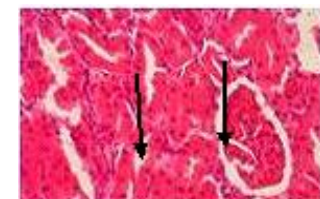

Figure 10. Cross section of the kidney of alloxanized rat administered 72 mg/kg body weight of extract (x400; H&E).

Therefore, changes in biochemical indices of organ function usually indicate impairment of the normal functioning of such organs [27]. The

biochemical indices investigated in the liver, kidney and serum of the animals in the present study are useful 'markers' for assessing the functional capacity of these organs.

Measurement of the activities of various enzymes in tissues and body fluids play a significant role in the investigation and diagnosis of diseases [28], and to a reasonable extent, the toxicity of chemical compounds including those in plant extracts [29]. Enzymes do not usually originate from serum, but rather are derived from disintegration, metabolism and turnover of tissues and blood cells. Therefore, leakage of enzymes from tissues and organs may become manifested in the serum as increased activity [28]. In this study, 'marker' enzymes were assayed based on their specific locations in cells, since it has been shown that the site of injury to the cell could be correlated and determined by assaying the level of activities of 'marker' enzyme in such cells [29]. Alkaline phosphatase is an ectoenzyme of the plasma membrane and is used to assess the integrity or damage to the plasma membrane [30,31]. The reduced liver and kidney alkaline phosphatase activity by alloxan accompanied by corresponding increase in the serum enzyme suggest permeability changes probably as a result of damage by oxidative products of alloxan. The loss of the aminotransferases (ALT and AST) from the liver and kidney with corresponding increases in the serum of alloxan treated rats is quite understandable since the enzymes are cytosolic in origin and any damage to plasma membrane will consequently lead to their leakage to the external milieu, in this case, the serum. The administration of the extract mitigated against these alterations in the liver and kidney enzymes conferring attenuation of alloxan toxicity on the extract.

Albumin, total bilirubin and globulin which constitute protein content of the cell can be used to assess the functional capacity of the liver [32]. The reduction in the levels of total protein, globulin and the computed albumin/globulin ratio by alloxan in the present study may be attributed to diminished synthetic function of the liver probably as a consequence of hepatocellular injury, enhanced catabolism or excessive loss from the body which might be more than the rate of synthesis [33]. The elevated levels of total and conjugated bilirubin may further corroborate the alloxan treatment related

toxic changes in the animals. These alloxan toxicities with respect to the total protein component of the serum of the animals were reduced in strength by all the doses of the extract with complete restoration/reversal by the 72 mg/kg body weight on total protein, globulin and albumin/globulin ratios.

Creatinine, urea, uric acid, electrolytes are important metabolites/molecules in the serum of animals that can be used to assess the normal functioning of the nephrons at both the globular and tubular levels. Apart from this, computed blood urea nitrogen/creatinine ratio can also give an idea of the organ that is affected since urea is produced by the liver and excreted by the kidney. The elevated levels of uric acid and computed blood urea nitrogen/creatinine ratio by the alloxan suggest glomerular dysfunction by the chemical compound, alloxan, whereas similar elevations in the serum electrolytes (Na⁺, K⁺, Cl⁻, Ca²⁺), as well as reduced levels of phosphate ion by alloxan indicates adverse effects on the tubular reabsorption of the electrolytes. The reabsorption of these biomolecules and electrolytes were attenuated by all the doses of the extract. It is worthy of note that the highest dose of the extract (72 mg/kg body weight) used in the present study exhibited complete reversal of the alloxan treatment related changes on the serum levels of Na⁺, K⁺, Cl⁻, Ca²⁺ and PO₄²⁻.

Alloxan exhibited systemic toxicity on haematological parameters investigated as evidenced by the decrease in RBC and factors relating to it (MCV, MCH and MCHC) and decrease in WBC and factors relating to it (neutrophils, basophils, eosinophils, lymphocytes, monocytes and platelets). The reductions in the levels of the haematological parameters by alloxan may be due to imbalance or absence of equilibrium in or between the rate of synthesis/production of the haematological parameters and their catabolism/destruction [34], as a consequence of oxidative products or reactive species generated by alloxan. The extract however mitigated/attenuated the toxic effects of alloxan on the blood parameters and this might lead to restoration of the functional capacity of the blood.

Alloxan, a urea derivative causes selective necrosis of organs in rats [25] and its reduction product, dialuric acid establishes a redox cycle with the formation of superoxide radicals [35]. The preservation of structural toxicity caused

alloxan was further exhibited by all the doses of the extract on the histoarchitecture of the liver and kidney of rats.

CONCLUSION

Overall, the aqueous extract of *F. agrestis* stems attenuated alloxan-induced functional and structural toxicities in rats. Further studies to isolate the compound that bring about this relief from alloxan-induced toxicity is necessary.

ACKNOWLEDGEMENTS

The authors are grateful to the technical assistance provided by Mr. Dele Aiyepoku of the Department of Biochemistry, University of Ilorin, Ilorin, Nigeria.

REFERENCES

- Skudelski T. The mechanism of action of alloxan and streptozotocin action in β - cells of the rat pancreas. *Physiol Res* 2001; 50:536-46.
- Dhanesha N, Joharapurkar A, Shah G, Dhote V, Kshirsagar S, Bahekar R, Jain M. Extendin-4 reduces glycemia by increasing liver glucokinase activity: an insulin independent effect. *J Diabetes* 2012;
- Grover JK, Yadav S, Vats V. Medicinal plants of India with anti-diabetic potential. *J Ethnopharmacol* 2002;81: 81-100.
- Dey L, Xie JT, Wang A, Wu J, Malekar SA Yuan CS. Anti-hyperglycemic effects of ginseng: comparison root and berry. *Phytomedicine* 2003;10: 600-5.
- Lenzen S. The mechanisms of alloxan- and streptozotocin-induced diabetes. *Diabetologia* 2008; 51:216-26.
- Adesokan AA, Oyewole OI, Turray Babara MS. Kidney and liver function parameters in alloxan-induced diabetic rats treated with Aloe barbadensis juice extract. *Sierra Leone J Biomed Res* 2009; 1(1):33-7.
- Iweala EEJ, Oludare FD. Hypoglycemic effect, biochemical and histological changes of *Spondias mombin* Linn. and *Parinari polyandra* Benth. seeds ethanolic extracts in alloxan-induced diabetic rats. *J Pharmacol Toxicol* 2011; 6(2):101-12.
- Onyije FM, Avwioro OG, Waritimi EG. Evaluation of nephrotoxic effect of *Bauhinia monandra* on the kidney of alloxan-induced diabetic rats. *J Pharma Clin Sci* 2012; 4:7-9.
- Yakubu MT, Akanji MA, Oladiji AT. Aphrodisiac potentials of the aqueous extract of *Fadogia agrestis* (Schweinf.Ex Heirn) stem in male albino rats. *Asian J Androl* 2005;7: 399-404.
- Ameen OM, Olatunji G, Atata RF, Usman LA. Antimicrobial activity, cytotoxic test and phytochemical screening of extracts of the stem of *Fadogia agrestis*. *Nigerian Soc Exp Biology J* 2011; 11(1): 79-84.
- Yakubu MT, Ogunro OB. Effects of aqueous extract of *Fadogia agrestis* stem in alloxan-induced diabetic rats. *Bangladesh J Pharmacol* 2014; 9: 356-63.
- National Research Council. Guide for the care and use of laboratory animals (8th ed.). National Academies Science Press. 2011; p. 161-96.
- Tietz NW. Clinical guide to Laboratory Tests. 3rd edition, W.B. Saunders Company, Philadelphia; 1995.
- Reitman S, Frankel S. A colourimetric method for determination of serum glutamate-oxaloacetate and pyruvate transaminase. *Am J Clin Pathol* 1957; 28:56-9.
- Wright PJ, Leathwood PD, Plummer DT. Enzymes in rat urine. Alkaline phosphatase. *Enzymologia* 1972; 42:317-27.
- Gornall AC, Bardawill CJ, David MM. Determination of serum protein by means of Biuret reaction. *J Biol Chem* 1949; 177:751-6.
- Doumas BT, Kwok-Cheung PP, Perry BW, Jendrzeczak B, McComb RB, Schaffer R, Hause LL. Candidate reference method for determination of total bilirubin in serum: development and validation. *Clin Chem* 1985; 31(11):1779-89.
- Skeggs LT, Hochstrasser, HC. Thiocyanate (colorimetric) method of chloride estimation. *Clin Chem* 10: 918-36.
- Fiske CH, Subbarow Y. The colorimetric determination of phosphorus. *J Biol Chem* 1925; 66:375-400.
- Veniamin MP, Varkirtzi C. Chemical basis of the carbamidodi-acetyl micro-method for estimation of urea, citrulline and carbamyl derivatives. *Clin Chem* 1970; 16:3-6.
- Bartels MD, Bohmer PW. Biochemistry at a glance. 1972. p. 42-55.
- Doumas BT, Watson WA, Biggs HG. Albumin standards and measurement of serum albumin with bromocresol green. *Clin Chem* 1971; 31: 87-92.
- Drury RA, Wallington EAC. Carleton's Histological Technique. 4th edition. Oxford, Oxford University Press; 1980.
- Krause WJ. The art of examining and interpreting histologic preparations. A student handbook. Parthenon Publishing Group, UK. p. 9-10.
- Etuk EU. Animal models for studying diabetes mellitus. *Agri Biol J North Am* 2010; 1: 130-4.
- Ankur R, Shahjad A. Alloxan induced diabetes: mechanisms and effects. *Int J Res Pharma Biomed Sci* 2012; 3(2):819-823.

27. Afolayan AJ, Yakubu MT. Erectile dysfunction management options in Nigeria. *JSexual Med* 2009; 6(4):1090-102.
28. Malomo SO. Toxicological implication of ceftriaxone administration in rats. *Nigerian J Biochem Molec Biol* 2000;15(1): 33-8.
29. Yakubu MT, Bilbis LS, Lawal M, Akanji M A. Evaluation of selected parameters of rat and kidney function following repeated administration of yohimbine. *Biokemistri* 2003; 15:50-6.
30. Akanji MA, Adegoke OA, Oloyede OB. Effect of chronic consumption of metabisulphate on the integrity of rat cellular system. *Toxicology* 1993; 81:173-9.
31. Shahjahan M, Sabitha KE, Mallika J, Shyamala-Devi CS. Effect of Solanum trilobatum against carbon tetrachloride induced hepatic damage in albino rats. *Indian J Med Res* 2004; 120: 94-198.
32. Ganong WF. Review of Medical Physiology. 20th Edition. Lange Medical Books/McGraw-Hill Medical Publishing Division. USA; 2001. p. 543.
33. Lakmichi H, Bakhtaoui FZ, Gadhi CA, Ezoubeiri A, El-Jahiri Y, El-Mansouri A, Zrara B, Loutfi K. Toxicity profile of the aqueous ethanol root extract of *Corrigiola telephiifolia* Pourr. (Caryophyllaceae) in rodents. *Evidence-Based Complementary and Alternative Medicine* 2011; volume 2011: Article ID 317090. 10 pages.
34. Yakubu MT, Adeshina AO, Ibrahim, OOK. Toxicological evaluation of aqueous leaf Extract of senna alata in pregnant wistar Rats. *Int J Current Res Rev* 2012;04:89-109.
35. Adaramoye OA, Osaimoje DO, Akinsaya MA, Nneji CM, Fafunso MA, Ademowo OG. Changes in antioxidant status and biochemical indices after acute administration of artemether, artemether-lumefantrine and halofantrine in rats. *Basic Clinical, PharmacolToxicol* 2008; 102: 412-8.