

**Original Article****Aqueous Leaf Extract of *Heliotropium indicum* Ameliorates Hyperglycaemia-Induced Tissue Complications in Albino Rats**

Rasheed Bolaji Ibrahim<sup>\*1</sup>, Jubril Olayinka Akolade<sup>2</sup>, Abdulhakeem Olarewaju Sulyman<sup>1</sup>, Saheed Sabiu<sup>1</sup>, Babalola Ola Yusuf<sup>3</sup>, Lateefah Badrudeen Yusuf<sup>1</sup>

Received: 14.07.2017

Accepted: 03.09.2017

**ABSTRACT**

**Background:** *Heliotropium indicum* is used by traditional medical practitioners in North Central Nigeria for the management of ailments including diabetes. However, the folkloric use of *H. indicum* as antidiabetic has been asserted, but its roles on the hyperglycemia-induced organ-specific complications are not yet scientifically proven. Thus, ameliorative effect of aqueous leaf extract of *H. indicum* on selected toxicological parameters in hyperglycaemic rats was investigated in this study.

**Methods:** Twenty-five rats were randomized into five groups. The study was carried out at the Animal Holding Unit, Biochemistry Department, University of Ilorin in 2013. Four groups were intraperitoneally administered singly with 150 mg/kg b.wt of alloxan to induce hyperglycemia. The normal control (NC) and hyperglycaemic control (HC) groups were administered 1 ml distilled water, while the reference group (HR) were administered 14.2 mg/kg b.wt of metformin and the test groups, H30 and H75 were administered 30 and 75 mg/kg b.wt, the extract respectively for fourteen days.

**Results:** The significantly increased ( $P < 0.05$ ) serum concentrations of tissue membrane bound enzymes (ALT, AST, ACP and ALP), direct and total bilirubin, urea and creatinine in HC indicating compromised tissue structures and functions in HC were attenuated. The significantly ( $P < 0.05$ ) reduced serum total protein, globulin and albumin in HC were significantly increased by both doses of the extract. The ameliorative role of the extract at the test doses was supported by the histological assessment of liver and kidney of the animals.

**Conclusion:** Aqueous leaf extract of *H. indicum* can be explored at the ethnobotanical dose of 30 and 75 mg/kg b.wt on the management of some of the tissue-specific disarrays associated with diabetes.

**Keywords:** *Heliotropium Indicum*, Hyperglycaemia, Kidney Function, Liver Function, Phytomedicine.

IJT 2018 (1): 19-26

**INTRODUCTION**

Diabetes mellitus (DM) is a chronic progressive metabolic syndrome characterized by hyperglycemia due to inadequacies in insulin secretion and/or action leading to derangements in the metabolism of carbohydrate and abnormalities in protein and lipid metabolism [1].

DM remains an important non-communicable disease of global concern affecting 415 million people with a progressively increasing prevalence in every studied population. It is one of the five

principal causes of death in the world led singly to about 5 million deaths in 2015 [2].

The complications of DM increase in prevalence with the increase in the prevalence of DM in all populations especially in the developing countries where management strategies are poor and not readily accessible. Disorders in tissue metabolism resulting from poorly managed hyperglycemia are the main cause of diabetic complications leading to damage to many organs including liver and kidney [3]. Thus, the deterrence and management of diabetic complications are considered very

1. Department of Biochemistry, Faculty of Pure and Applied Sciences, Kwara State University, Malete, Ilorin, Nigeria.

2. PhD of Biochemistry, Biotechnology and Genetic Engineering Advanced Laboratory, Sheda Science and Technology Complex, Sheda, Abuja, Nigeria.

3. Department of Biochemistry, Faculty of Life Sciences, University of Ilorin, Ilorin, Nigeria.

\*Corresponding Author: E-mail: ibrahimrasheedb@gmail.com

important objectives in managing and treating diabetes mellitus [4].

The use of plants for the prevention, management, and cure of diseases is as old as human awareness of diseases. About 80%-85% of population in developing countries relies largely on indigenous practices in meeting their primary health care needs [5].

The use of plants in managing diabetes and resultant complications has remained of choice due to the accessibility and affordability of plants and the fact that they are culturally acceptable since communities are aware of their source.

*Helitropium indicum* is one of such plants used by TMPs in North Central Nigeria on the management of diabetic complications [6,7]. It is an indigenous plant in Ayurvedic medicine. The whole plant and its parts have been widely used in diseases relating to wounds, inflammations, and infections [8, 9]. It is usually associated with the moist soils of the lowland tropics close to rivers and lakes, and waste places [10]. It is found widely in North Central Nigeria and known as Agogo Igun or Ogbe Akuko (Yoruba - Nigeria) and Kalkashin orkorama (Hausa-Nigeria). Various parts of the plant are used in several parts of Africa in the treatment of sexually transmitted diseases or infections, inflammations and other forms of wounds [6, 11, 12].

The antihyperglycemic potency of the whole plant and its parts and their ameliorative effect on some complications of diabetes has been earlier reported [7, 13, 14]. However, its effect on tissue specific hyperglycemia-induced complications is yet to be assessed. Hence, this research was conducted to investigate the ameliorative effect or otherwise, of the Aqueous Leaf Extract of *H. indicum* on hyperglycemia-induced tissue complications.

## MATERIALS AND METHODS

### *Plant Material and Chemicals*

The fresh leaves of *H. indicum* were obtained from the vegetable farm by the riverside beside 'Oja tuntun' market in Ilorin, Kwara State, Nigeria in 2013. Identification was carried out in the herbarium of the Plant Biology Department of the University of Ilorin, Ilorin, Nigeria, where voucher specimens, with voucher number UIH015, were deposited. Alloxan monohydrate and p-nitrophenylphosphate were products of Sigma Chemical Company, St. Louis, Mo, USA. Assay

kits for AST, ALT, glucose, urea, creatinine, albumin, and bilirubin were products of Randox Laboratories Ltd., Antrim, UK. All other chemicals were of analytical grades and prepared in all-glass apparatus using distilled water.

### *Experimental Animals*

Twenty-five Albino rats (*Rattus norvegicus*) of average weight of  $110.88 \pm 5.33$  were obtained from the animal holding unit of the Department of Biochemistry, University of Ilorin, Ilorin, Kwara State. The animals were acclimatized to standard laboratory housing conditions for two weeks before the commencement of the experiment.

The research conformed strictly to the Principles of Laboratory Animal Care (NIH Publication No. 85-23, 1996). The research protocols were requested to and approved by Department of Biochemistry, University of Ilorin, Ilorin, Nigeria.

### *Preparation of Plant Extract*

A known weight (200 gr) of the fresh leaves of *H. indicum* was manually pulverized using 1000 ml of distilled water. The pulverized leaf juice was left to settle for about five hours and thereafter sieved twice-using muslin cloth. This was done to emulate the method used by herbal practitioners in the environment from which the extract was obtained in the extraction of the plants material. The slightly greenish brown juice obtained was lyophilized and stored in sealed container under refrigeration.

### *Dosage Determination*

From ethnobotanical survey through communications with TMPs, approximately 250 ml of the extracted juice is taken once a day for management of diabetes by a patient of 70 kg average weight, while obese patients are given same volume two-three times daily. Separately lyophilized 250 ml of the plant juice yielded 2.11 gr of the extract. Thus, a dosage of 30 mg/kg b. wt. was extrapolated and adapted to ascertain the acclaimed antihyperglycemic activity of the extract.

### *Animal Grouping and Extract Administration*

Twenty-five rats of both sexes (housed separately) were allowed access to standard rat pellets and water *ad libitum*. About 12 h before the measurement of fasting blood glucose (FBG) to ascertain hyperglycemia, the feeds were temporarily withdrawn. The animals were randomly selected into five groups of five animals each as follows:

1. NC: Normal Control (normoglycemic rats receiving 1 ml of distilled water)
2. HC: Non-Treated Control (hyperglycemic rats receiving 1 ml of distilled water)
3. HR: Hyperglycemic rats treated with reference drug (14.2 mg/kg b. wt Metformin)
4. H30: Hyperglycemic rats treated with 30 mg/kg b.wt. of *H. indicum* extract
5. H75: Hyperglycemic rats treated with 75 mg/kg b.wt of *H. indicum* extract

### **Induction of Experimental Hyperglycemia**

Chemical induction of “hyperglycemia”, the main feature of diabetes mellitus, was done using the method [15] with little modification as elucidated below. Animals were fasted for 12 h and then were subjected to a single intraperitoneal injection of alloxan monohydrate, 150 mg/kg b. wt, freshly dissolved in normal saline solution. A fifth of the rats was also given normal saline to serve as normoglycemic control (NC). Fasting blood glucose was determined using multicare-in multiparameter diagnostic device (Biochemical Systems International, Arezzo-Italia) and compatible strips 48 h after alloxan injection. Rats showing FBS above 250 mg/dl and sustained hyperglycemia for the next 72 h (5 d after alloxan induction) were considered diabetic and used in the study.

### **Preparation of Serum and Tissues Homogenates**

The rats were anesthetized, sacrificed and blood was collected. The sera were collected and stored under refrigeration before the determination of the liver and kidney function indices and the activity of membrane maker enzymes. In addition, sacrificed carcasses were dissected; the liver and kidney were excised. The livers were weighed, rinsed and homogenized in ice cold 50 mM Tris / HCl buffer pH 7.5 [16] containing Triton x-100 at a final concentration of 0.5% [17]. The kidneys were immediately suspended in and later were homogenized using ice-cold 0.25M sucrose solution (1:5<sup>w/v</sup>). The homogenates were stored under refrigeration (each in a labeled specimen bottle).

### **Biochemical Analysis**

Serum concentrations of direct and total bilirubin, albumin, globulin, urea, creatinine, and activities of

AST and ALT were determined using commercially available diagnostic kits obtained from Randox Laboratories Ltd., Antrim, UK. Protein concentration of the homogenates and serum were determined [18], alkaline phosphatase (ALP) and Acid phosphatase were assayed using the method [19, 20].

### **Histological Examination of Rat Liver and Kidney**

A specimen of the liver and kidney of each of the experimental group was fixed in 10% formalin. The specimens were dehydrated in ascending grades of ethanol, cleared in xylene, and processed to molten paraffin wax blocks, sectioned (5  $\mu$ m thick) and stained with Hematoxyline and Eosine stain. They were then examined using light microscopy for demonstration of hyperglycaemia induced pathological changes and the treatment with *H. indicum* [21].

### **Statistical Analysis**

The results were expressed as mean  $\pm$ Standard error of mean (SEM) of five replicates (n=5). Data obtained were subjected to one-way analysis of variance and means found to be significantly different at  $P<0.05$  were separated by Duncan Multiple Range Test.

## **RESULTS**

The serum activities of tissue membrane bound enzymes (ALT, AST, ACP, and ALP) which are high in hyperglycemic rats indicating compromised tissue structures in HC throughout the experimental period were significantly reduced in the rats treated with aqueous leaf extract of *H. indicum* (Table 1). The activities of the enzymes in the liver (Table 2) and kidney (Table 3) were significantly increased after 14 d of treatment with extract at both folkloric dosages. The elevated serum albumin (Figure 1), total and direct bilirubin (Figure 2), urea and creatinine (Figure 3) in HC were attenuated by both doses of the extract and the reduction in serum total protein and globulin observed in the HC were significantly increased by both doses of the extract in the treated rats after 14 d (Figure 1). It was further supported by the histological assessment of liver and kidney of the experimental animals (Figure 4 and Figure 5).

**Table 1.** Effect of oral administration of aqueous leaf extract of *H. indicum* on serum activities of marker enzymes in alloxan-induced diabetic rats.

	Serum Enzyme Activity			
	ALT (U/l)	AST (U/l)	ALP (nM/min/ml)	ACP (nM/min/ml)
NC	40.67±5.59 <sup>a</sup>	225.83±14.24 <sup>a</sup>	78.84±23.54 <sup>a</sup>	65.86±0.96 <sup>a</sup>
HC	170.00±15.00 <sup>c</sup>	483.33±58.33 <sup>b</sup>	171.16±4.77 <sup>b</sup>	151.92±23.24 <sup>b</sup>
HR	40.83±5.67 <sup>a</sup>	229.67±53.53 <sup>a</sup>	142.54±14.59 <sup>b</sup>	78.33±9.47 <sup>a</sup>
H30	131.17±38.54 <sup>bc</sup>	173.83±63.83 <sup>a</sup>	123.46±16.69 <sup>ab</sup>	60.49±14.40 <sup>a</sup>
H75	100.50±4.50 <sup>ab</sup>	114.00±11.00 <sup>a</sup>	91.19±8.97 <sup>a</sup>	63.52±23.81 <sup>a</sup>

Values are expressed as mean of five replicates ± S.E.M

Values along a column with different superscripts are significantly ( $P<0.05$ ) different.

NC=normal control; HC=Hyperglycaemic control; HR=Hyperglycaemic+14.2mg/kg b. wt metformin; H75=Hyperglycaemic+ *H. indicum* (75 mg/kg b.wt); H30=Hyperglycaemic+ *H. indicum* (30 mg/kg b.wt).

**Table 2.** Effect of oral administration of aqueous leaf extract of *H. indicum* on the activities of marker enzymes in the Liver of alloxan-induced diabetic rats.

	Liver Enzyme Activity			
	ALT (U/l)	AST (U/l)	ALP (nM/min/ml)	ACP (nM/min/ml)
NC	1410.00±300.49 <sup>a</sup>	2890.00±554.34 <sup>a</sup>	351.85±35.54 <sup>a</sup>	1540.12±438.59 <sup>ab</sup>
HC	458.00±64.00 <sup>d</sup>	1315.00±85.00 <sup>b</sup>	186.87±27.78 <sup>d</sup>	989.89±66.82 <sup>a</sup>
HR	1135.00±18.03 <sup>a</sup>	2790.00±330.00 <sup>a</sup>	335.02±45.21 <sup>a</sup>	1352.04±183.29 <sup>ab</sup>
H30	2545.00±27.84 <sup>c</sup>	4360.00±170.00 <sup>c</sup>	468.01±3.67 <sup>b</sup>	2793.17±51.46 <sup>c</sup>
H75	3074.00±84.79 <sup>b</sup>	2750.00±401.49 <sup>a</sup>	596.80±12.74 <sup>c</sup>	1837.91±242.48 <sup>b</sup>

Values are expressed as mean of five replicates ± S.E.M

Values along a column with different superscripts are significantly ( $P<0.05$ ) different.

NC=normal control; HC=Hyperglycaemic control; HR=Hyperglycaemic+14.2mg/kg b. wt metformin; H75=Hyperglycaemic+ *H. indicum* (75mg/kg b.wt); H30= Hyperglycaemic+ *H. indicum* (30 mg/kg b.wt).

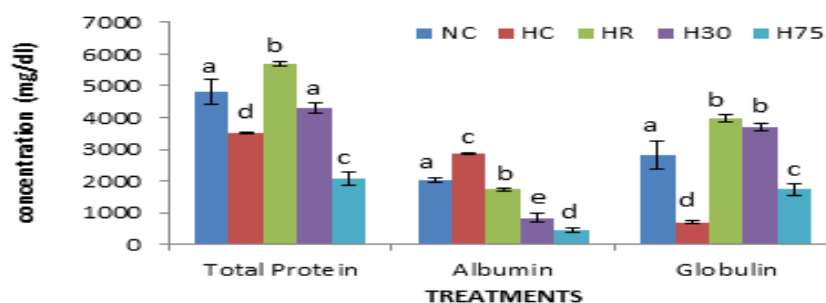
**Table 3.** Effect of oral administration of aqueous leaf extract of *H. indicum* on the activities of marker enzymes in the kidney of in alloxan-induced diabetic rats.

	Kidney Enzyme Activity	
	ALP (nM/min/ml)	ACP (nM/min/ml)
NC	808.92±25.68 <sup>a</sup>	687.15±66.59 <sup>a</sup>
HC	111.95±16.84 <sup>b</sup>	304.39±19.79 <sup>c</sup>
HR	822.39±17.39 <sup>a</sup>	982.22±15.10 <sup>ab</sup>
H30	893.09±36.49 <sup>a</sup>	839.76±147.66 <sup>ab</sup>
H75	1124.58±38.31 <sup>c</sup>	1137.56±154.05 <sup>b</sup>

Values are expressed as mean of five replicates ± S.E.M

Values along a column with different superscripts are significantly ( $P<0.05$ ) different.

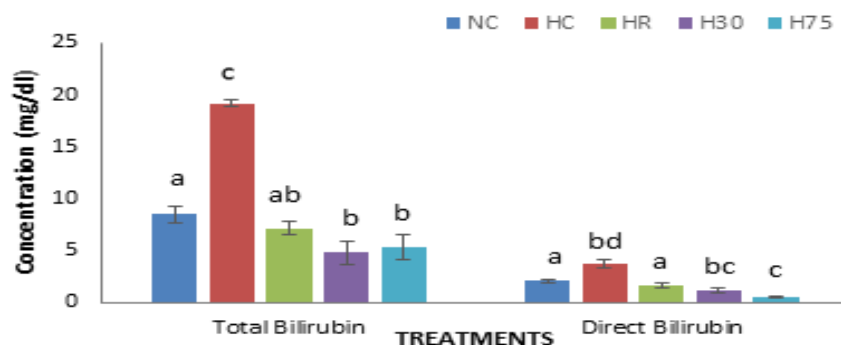
NC = normal control; HC = Hyperglycaemic control; HR = Hyperglycaemic+14.2mg/kg b. wt metformin; H75 = Hyperglycaemic+ *He. indicum* (75mg/kg b.wt); H30= Hyperglycaemic+ *H. indicum* (30 mg/kg b.wt).

**Figure 1.** Effect of oral administration of aqueous leaf extract of *H. indicum* on liver function parameters of alloxan induced hyperglycemic rats.

Values are expressed as mean of five replicates ± S.E.M

Bars of a parameter with different alphabets are significantly ( $P<0.05$ ) different

NC = normal control; HC=Hyperglycaemic control; HR = Hyperglycaemic +14.2mg/kg b. wt metformin; H75 = Hyperglycaemic + *H. indicum* (75mg/kg b.wt); H30= Hyperglycaemic + *H. indicum* (30 mg/kg b.wt).

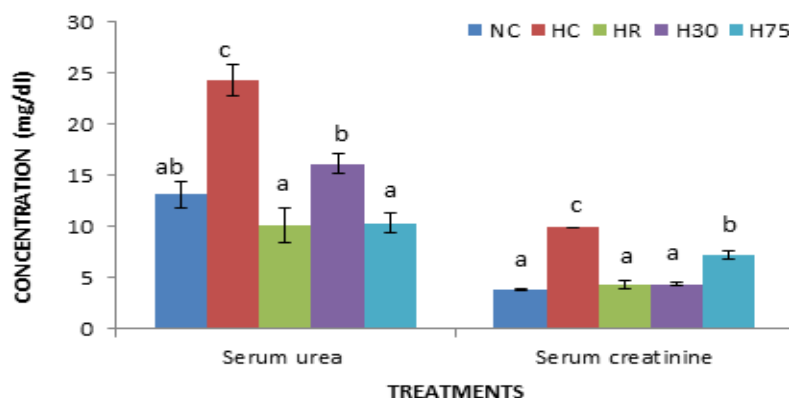


**Figure 2.** Effect of oral administration of aqueous leaf extract of *H. indicum* on serum total and direct bilirubin of alloxan induced diabetic rats.

Values are expressed as mean of five replicates  $\pm$  S.E.M

Bars of a parameter with different alphabets are significantly ( $P < 0.05$ ) different

NC=normal control; HC=Hyperglycaemic control; HR=Hyperglycaemic+14.2mg/kg b. wt metformin; H75=Hyperglycaemic+ *H. indicum* (75mg/kg b.wt); H30= Hyperglycaemic+ *H. indicum* (30 mg/kg b.wt).

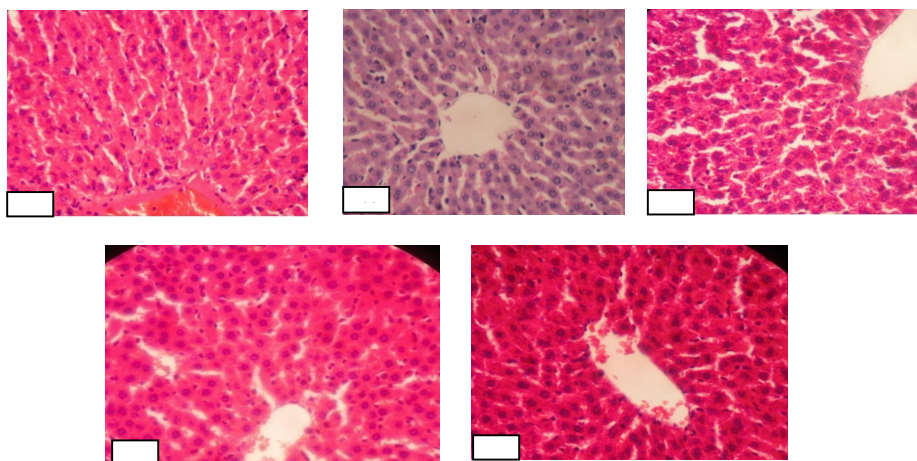


**Figure 3.** Effect of oral administration of aqueous leaf extract of *H. indicum* on kidney function indices of alloxan induced diabetic rats.

Values are expressed as mean of five replicates  $\pm$  S.E.M

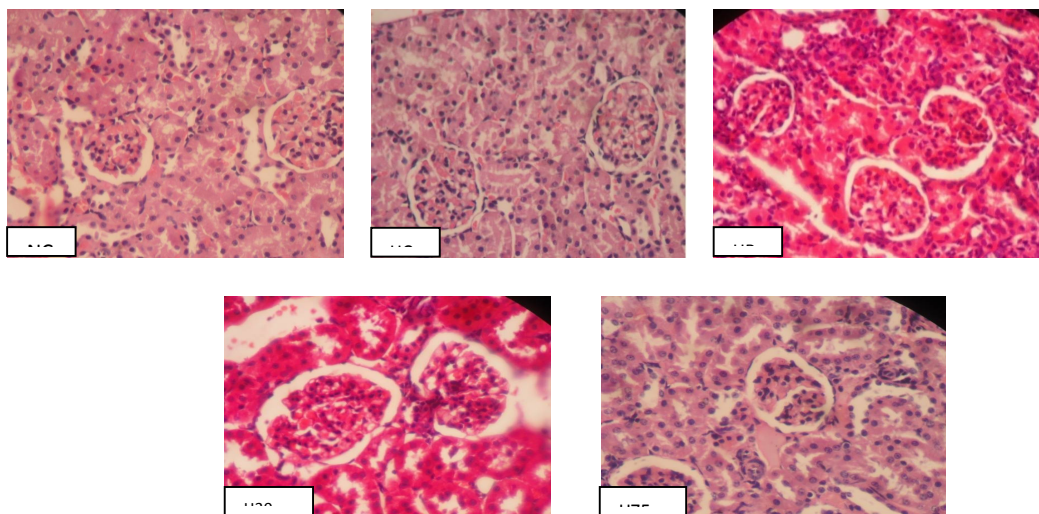
Bars of a parameter with different alphabets are significantly ( $P < 0.05$ ) different

NC=normal control; HC=Hyperglycaemic control; HR=Hyperglycaemic+14.2mg/kg b. wt metformin; H75=Hyperglycaemic+ *H. indicum* (75mg/kg b.wt); H30=Hyperglycaemic+ *H. indicum* (30 mg/kg b.wt).



**Figure 4.** Photomicrographs (X400) of Liver of Normal Control Rats (NC), Hyperglycaemic Control Rats (HC), Hyperglycaemic treated with 14.2mg/kg b. wt. of Metformin (HC), Hyperglycaemic Rats treated with 30mg/ kg b. wt of *H. indicum* (H30) and Hyperglycaemic Rats treated with 75mg/kg b. wt of *H. indicum* (H75).





**Figure 5.** Photomicrographs of Kidney of Normal Control Rats (NC), Hyperglycaemic Control Rats (HC), and Hyperglycaemic Rats treated with 14.2mg/kg b wt of Metformin (HR) Hyperglycaemic Rats treated with 30mg/kg b wt of *H. indicum* (H30) and Hyperglycaemic Rats treated with 75mg/kg b wt of *H. indicum* (H75).

## DISCUSSION

Persistent hyperglycaemia is the main cause of the changes in kidney and liver function in diabetes mellitus. Aggravated increase in the rate of protein and lipid glycation, forming advanced glycation products (AGEs), oxidative stress, polyol pathway activation and hexosamine flux, causing inflammation and damage – are all consequences of hyperglycemia [22].

The elimination of urea and creatinine from the plasma is the primary function of glomerulus. Thus, the serum concentrations of urea and creatinine are parameters of significance in the assessment of renal sufficiency. Higher than normal levels of serum urea and creatinine are indications of impairment in renal function [23]. The significant reduction in the serum concentration of urea and creatinine of rats treated with the two folkloric dosages of the extract when compared with the hyperglycemic control rats signifies the ameliorative effect of the extract on the hyperglycemia-induced compromise in the rats' kidney function.

Albumin, total bilirubin, and globulin are mixtures of protein molecules whose relative concentrations are considered in the assessment of liver cells' functional integrity through regulation of osmotic pressure and the secretory capability of the liver [24]. The reduced total protein concentration, globulin, albumin and total bilirubin demonstrated by the hyperglycemic control rats, which is indicative of hyperglycemia-induced reduced secretory ability of the liver and reduced

hepatobiliary function, are restored by the extract at both doses employed. This underlies the beneficial role of the extract in the amelioration of the hyperglycemia-induced liver complications.

The activities of various enzymes in particular tissues (and very important body fluids) are significant and well-known parameters in disease investigation and diagnosis. This is because activities of enzymes sum up the catalytic influence of several factors (e.g. inhibitors and activators) during such pathological conditions. Enzymes usually do not originate from the serum, but rather are derived from the disintegration, metabolism, and turnover of tissues and blood cells. Therefore, enzymes from diseased tissues and organs (e.g. during cardiac, hepatic and neoplastic diseases) may become manifested in the serum resulting in increased expressed activity. This is often accompanied by concomitant decrease in enzyme activity in affected tissues and organs.

The two transaminases in use in diagnostic enzymology are AST and (ALT). Transaminases are normally intracellular enzymes with the low levels found in the plasma representing the release of cellular content during normal cell turnover. AST is found in both the cytoplasm as well as the mitochondria of organs, its inordinate increased activity in the serum suggest severe and chronic damage that might have extended beyond the cytoplasm [25]. Alkaline phosphatase has been employed in the assessment of the integrity of plasma membrane and endoplasmic reticulum [26] and acid phosphatase is an indicator of damage to the lysosomal membrane [27].

The increase in serum activities observed for the marker enzymes (ALP, ALT, and AST) and the concomitant decrease in tissue activities observed in hyperglycemic control rats in this study have been earlier reported [28], associated with hemolysis that result from hyperglycemia-induced hepatomegaly [29, 30]. Administration of some antioxidants to diabetic rats normalized the elevated levels of serum marker enzymes ALT, AST, and ALP induced in response to diabetes mellitus [31].

Therefore, the significant reduction in serum activities of all the enzymes studied and the significant increase in the tissue activities of hyperglycemic rats treated with the aqueous extract of *H. indicum* leaf can be linked to its antihyperglycemic activity [7], prevented the organ specific complications. The ameliorative effects can also be generally adduced to the array of phytoconstituents present in the extract earlier reported possessing anti-inflammatory and antioxidant activity [32, 33].

## CONCLUSION

Aqueous leaf extract of *H. indicum* can thus be explored at the ethnobotanical doses of 30 and 75 mg/kg body weight in the management of some hyperglycemia-induced tissue-specific complications associated with diabetes mellitus.

## ACKNOWLEDGEMENTS

The authors are thankful to the Laboratory Technologists of Biochemistry Department, University of Ilorin for providing some technical supports in this study. The authors declare no conflict of interest with respect to this research, authorship, and/or publication of this article.

## REFERENCES

- Ezuruike UF, Prieto JM. The use of plants in the traditional management of diabetes in Nigeria: Pharmacological and toxicological considerations. *J Ethnopharmacol* 2014;155(2):857-924.
- International Diabetes Federation. *International Diabetes Federation Diabetes Atlas*, 2015.
- Kawahito S, Kitahata H, Oshita S. Problems associated with glucose toxicity: role of hyperglycemia-induced oxidative stress. *World J Gastroenterol* 2009;15(33):4137-8.
- America Diabetes Association. *Standards of medical care in diabetes-2016 abridged for primary care providers*. *Clinical Diabetes* 2016;34(1):3-4.
- Prakash O, Kumar R, Srivastava R, Tripathi P, Mishra S. Plants explored with anti-diabetic properties: A review. *Am J Pharmacol Sci* 2015;3(3):55-66.
- Atawodi SE-O, Olowoniyi OD, Obari MA, Ogaba I. Ethnomedical Survey of Adavi and Ajaokuta Local Government Areas of Epiraland, Kogi State, Nigeria. *Annu Res Rev Biol* 2014;4(24):4344-5.
- Ibrahim RB, Akolade JO, Aladodo RA, Okereke OE, Akande SA. Glucose and Lipid Lowering Potentials of *Heliotropium indicum* L. Leaves in Alloxan-Induced *Hyperglycaemic Rats*. *Not Sci Biol* 2016;8(4):414-21.
- Srinivas K, Rao M, Rao S. Anti-inflammatory activity of *Heliotropium indicum* linn. and *Leucas aspera spreng.* in albino rats. *Indian J Pharmacol* 2000;32(1):37-8.
- Reddy JS, Rao PR, Reddy MS. Wound healing effects of *Heliotropium indicum*, *Plumbago zeylanicum* and *Acalypha indica* in rats. *J Ethnopharmacol* 2002;79(2):249-51.
- Holm L, Del Y, Holm E, Panchon T, Herberger T. *World weeds: Natural Histories and Distributions*. John Wiley and Sons Inc: New York, 1997.
- Ebenezer IO. Preliminary Investigations on the Ethnomedicinal Plants of Akoko Division, South West Nigeria. *Glob J Health Sci* 2011;3(2):84-5.
- Nordeng H, Al-Zayadi W, Diallo D, Ballo N, Paulsen BS. Traditional medicine practitioners' knowledge and views on treatment of pregnant women in three regions of Mali. *J Ethnobiol Ethnomed* 2013;9(1):67-8.
- Aqheel MA, Janardhan M, Durrai vel S. Evaluation of the antihyperglycaemic activity of methanolic extract of root of *Heliotropium indicum* streptozotocin and alloxan induced diabetic rats. *Indian J Res Pharm Biotechnol* 2013; 1:707-10.
- Mohammad SA, Abdul Nabi S, Marella S, Thandaiah KT, Venkateshwarulu M, Kumar J, Rao CA. Phytochemical screening and antihyperglycaemic activity of *Heliotropium indicum* whole plant in Streptozotocin induced diabetic rats. *J Appl Pharm Sci* 2014;4 (12): 065-71.
- Sharma N, Garg V, Paul A. Antihyperglycemic, antihyperlipidemic and antioxidative potential of *Prosopis cineraria* bark. *Indian J Clin Biochem* 2010; 25 (2):193-200.
- Ugochukwu NH, Babady NE. Antioxidant effects of *Gongronema latifolium* in hepatocytes of rat models of non-insulin dependent diabetes mellitus. *Fitoterapia* 2002;73:612-8.
- Muhammad NO, Oloyede OB, Yakubu MT. Effect of terminalia catappaseed meal-based diet on the alkaline and acid phosphatases activities of some selected rat tissues. *Recent Prog Med Plants* 2006;13: 272-9.
- Gornall AG, Bardawill JC, David MM. Determination of serum proteins by means of Biuret reaction. *J Biol Chem* 1949; 177:751-60.
- Wright P, Leathwood P, Plummer D. Enzymes in rat urine: alkaline phosphatase. *Enzymologia* 1972;42(4):317-27.

20. Wright P, Leathwood P, Plummer D. Enzymes in rat urine: acid-phosphatase. *Enzymologia* 1972; 42(6):459-68.
21. Krause WJ. The art of examining and interpreting histologic preparations: A student handbook: CRC Press; 2001.p.9-10.
22. Wolf G, Ziyadeh FN. Cellular and molecular mechanisms of proteinuria in diabetic nephropathy. *Nephron Physiol* 2007;106(2):p26-p31.
23. Saba H, Batinic-Haberle I, Munusamy S, Mitchell T, Lichti C, Megyesi J, et al. Manganese porphyrin reduces renal injury and mitochondrial damage during ischemia/reperfusion. *Free Radical Biol Med* 2007;42(10):1571-8.
24. Guyton AC, Hall JE. Textbook of Medical Physiology Harcourt International Edition, W.B Saunder Company Philadelphia, 2000.p. 279-81.
25. Kingsley O, Iyere OO, Georgina EO. Effects of Aqueous Root Extract of *Treculia africana* on Glucose, Serum Enzymes and Body Weight of Normal Rabbits. *Br J Pharmacol Toxicol* 2011;2(4):159-62.
26. Akanji MA, Olagoke OA, Oloyede OB. Effect of chronic consumption of metabisulphite on the integrity of the rat kidney cellular system. *Toxicol* 1993;81(3):173-9.
27. Collins A, Lewis D. Lysosomal enzyme level in blood of arthritic rats. *Biochem Pharmacol* 1971; 28:251-3.
28. Nwanjo HU. Studies on the Effect of Aqueous Extract of *Phyllanthus niruri* Leaf on Plasma Glucose Level and Some Hepatospecific Markers in Diabetic Wistar Rats. *Int Lab Med* 2007;2(2): 1-18.
29. Hickman IJ, Russell AJ, Prins JB, Macdonald GA. Should patients with type 2 diabetes and raised liver enzymes be referred for further evaluation of liver disease? *Diabetes Res Clin Pract* 2008;80(1):e10-e2.
30. Muhammad K, Saeed YD, Rongji D. Attenuation of Biochemical Parameters in Streptozotocin-induced Diabetic Rats by Oral Administration of Extracts and Fractions of *Cephalotaxus sinensis*. *J Clin Biochem Nutr* 2008;42(1):21-8.
31. Abdel-Mageed N. Efficacy of some antioxidants on certain biochemical parameters in blood of diabetic rats. *Egypt Pharm J* 2005;4:125-34.
32. Abubakar MS, Musa AM, Ahmed A, Hussaini IM. The perception and practice of traditional medicine in the treatment of cancers and inflammations by the Hausa and Fulani tribes of Northern Nigeria. *J Ethnopharmacol* 2007; 111(3): 625-9.
33. Santhosha D, Ramesh A, Hemalatha E, Nagulu M. Phyto chemical screening and Antioxidant activity of ethanolic extract of *Heliotropium indicum*. *Int Res J Pharm* 2015;6 (8): 567-72.