

## Research Paper:

# The Effect of Saffron (*Crocus Sativus*) on Oxymetholone-induced Hepatic and Renal Injury in Rats



Reza Kheirandish<sup>1</sup> , Mehdi Saberi<sup>2</sup> , Shahrzad Azizi<sup>1\*</sup> , Reza Khakdan<sup>2</sup> , Zahra Kordzadeh Kermani<sup>2</sup>

1. Department of Pathobiology, Faculty of Veterinary Medicine, Shahid Bahonar University of Kerman, Kerman, Iran.

2. Department of Clinical Science, Faculty of Veterinary Medicine, Shahid Bahonar University of Kerman, Kerman, Iran.



**How to cite this paper** Kheirandish R, Saberi M, Azizi Sh, Khakdan R, Kordzadeh Kermani Z. The Effect of Saffron (*Crocus Sativus*) on Oxymetholone-induced Hepatic and Renal Injury in Rats. Iranian Journal of Toxicology. 2021; 15(4):233-240.  
<http://dx.doi.org/10.32598/ijt.15.4.435.2>

<http://dx.doi.org/10.32598/ijt.15.4.435.2>



### Article info:

**Received:** 22 Apr 2021

**Accepted:** 21 Jun 2021

**Online Published:** 01 Oct 2021

### \* Corresponding author:

**Shahrzad Azizi, DVM, PhD.**

**Address:** Department of Pathobiology,  
Faculty of Veterinary Medicine, Shahid Bahonar University of Kerman,  
Kerman, Iran.

**E-mail:** [azizi@uk.ac.ir](mailto:azizi@uk.ac.ir)

## ABSTRACT

**Background:** Oxymetholone, an anabolic-androgenic steroid, has been used to treat some diseases. The abuse of this compound, especially for muscle growth, has severe oxidative side effects on the liver and kidneys. Oxidative stress and free radicals are responsible for the development of various diseases. Phytochemicals are sources of polyphenols, flavonoids, saponins, etc. and may act as scavengers of free radicals. Saffron (*Crocus sativus*) has considerable antioxidant properties, which may be useful in reversing or preventing these negative effects.

**Methods:** To evaluate the effects of saffron on the liver and kidneys degenerative changes induced by oxymetholone, 24 male Wistar rats were used. The rats were randomly divided into four groups of six rats each as: a) sham (normal saline, 40 mg/kg/day), b) saffron control (40 mg/kg/day), c) oxymetholone (50 mg/rat), and d) treatment group [saffron (40 mg/kg/day)+oxymetholone (50 mg/rat)]. The course of examination was 30 days.

**Results:** After one month, the sham and saffron control groups had normal histological findings. The treatment group with saffron showed a significant reduction in the hepatic and renal degenerative changes induced by oxymetholone compared to those observed in group.

**Conclusion:** Based on the histopathological results, the use of saffron produced protective effects against the degenerative changes in rats' liver and kidneys induced by oxymetholone.

**Keywords:** *Crocus sativus*, Histopathology, Kidneys, Liver, Oxymetholone

## Introduction

Oxymetholone, a derivative of testosterone, is a 17- $\alpha$ -alkylated anabolic-androgenic steroid [1]. For the anabolic properties, like promotion of muscle growth, it has been used in the treatment of such conditions, as HIV-related muscle wasting disorder, growth impairment in children, and damaged myocardium in heart failure [2, 3]. Its abuse by some athletes is prohibited because of the side effects.

This steroid promotes androgenic effects, such as vocal changes and hair loss, and may cause hepatic damages, i.e., cholestatic jaundice and tumors [1, 2]. Also, the increase in Hemoglobin (Hb), Hematocrit (HCT), Glutamic Oxaloacetic Transaminase (SGOT), and Glutamic Pyruvic Transaminase (SGPT) in the serum of some athletes who take oxymetholone have caused negative effects on their bones and liver [4]. Oxymetholone reduces antioxidant activity and catalase levels, and increases free radicals, oxidative stress, and malondialdehyde in the liver, indicating lipid damages [5].

Many of the risk factors lead to liver injury, hepatocyte death, fibrosis, cirrhosis, and eventually Hepatocellular Carcinoma (HCC). Treatment of the liver damages at the early stages will reduce the risk of HCC [6]. Infections, toxins, certain diseases and medications not only lead to liver damages but may also result in kidney dysfunction and intrinsic renal injuries [7-9]. The early treatment of acute kidney injuries is essential because of the limited therapies available for the established cases [7-9]. Medicinal plants may have the potential to prevent the side effects of some harmful agents by supporting the immune system. Plant-based medicines have been used to treat certain diseases for many years, and have important roles in therapeutic protocols [10-12].

Saffron (*Crocus sativus*) is a plant that is used as a spice because of its taste and aroma, and is usually cultivated in some countries, such as Iran, Spain, and Italy [13, 14]. It has numerous pharmacological effects, such as antioxidant, antitumor, anti-inflammatory, hypolipidemic, and anticonvulsant properties. It also increases HDL in the serum and reduces the hepatic enzymes in fatty liver disease [13, 15]. Also, saffron has protective effects on the liver and kidneys because of its health-promoting properties [7]. The objective of this study was to evaluate the effects of saffron on reducing the hepatotoxicity and renal injuries induced by oxymetholone.

## Materials and Methods

**Animals:** A group of 24 male Wistar rats, weighing 200-250 g, were used in this study, all of them were housed in cages and fed standard diet (pellets containing 15% protein supplied by Javaneh Co., Iran) and tap water ad libitum. They were kept under a 12-hr light/dark cycle at a controlled room temperature of  $22 \pm 2^\circ\text{C}$ .

**Experimental design:** This experimental trial was conducted, using saffron in its conventional form available in the market. Dried saffron was dissolved in distilled water at a dose of 40 mg/kg and oxymetholone was mixed in normal saline at 50 mg/rat. The animals received these solutions by oral gavage once a day for one month. The rats were randomly divided into four groups of six rats each as follows: a) controls, b) saffron, c) oxymetholone and, d) treatment (oxymetholone+saffron). Animals in the control and saffron groups received normal saline and saffron (40 mg/kg/day) by gavage, respectively. The rats in the third group received the oxymetholone solution at 50 mg per rat. In the treatment group, oxymetholone (50 mg/rat) and saffron (40 mg/kg) were given in combination to each rat once per day.

**Sampling and histopathological preparation:** Twenty-four hours after the last treatment, the rats were sacrificed by injection of ketamine (5%/body weight) and dissected to remove the liver and kidneys. The tissue samples were fixed in 10% formalin at neutral pH for 48 hours, then dehydrated, using ethyl alcohol, and cleared by xylene. Following this process, 5  $\mu\text{m}$  thick sections were made, embedded in paraffin, and stained with hematoxylin and eosin. These sections were subsequently examined under light microscopy (Olympus CX31, Japan). The hepatic degenerative changes observed in the slides were graded as normal (0), mild (+1), moderate (+2), and severe (+3).

**Statistical analyses:** Statistical differences were analyzed among the groups by one-way Analysis of Variance (ANOVA). A P-value of  $<0.05$  was considered as being statistically significant.

## Results

**Liver histopathological Results:** The results of the statistical analyses for the grades of hepatic degenerative changes showed significant differences between the oxymetholone and treatment groups (Table 1). The cellular structures in the liver tissue samples from the control and saffron groups were normal. The hepatocytes had light eosinophilic cytoplasm, with spherical and vesicular nuclei in the center (Figure 1A). In the oxymetholone group, severe degenerative changes (grade+3) were observed in three samples, including cell swelling and cytoplasmic vacuolation. The sinusoids were unclear because of the swellings (Figure 1B). Also, there was moderate degenerative changes (grade+2) in two rats, and mild hepatocyte vacuolation (grade+1) in one rat (Figure 1C). In the treatment group (oxymetholone+saffron), three rats showed normal hepatocyte structures (grade zero) with vesicular nuclei. In the remaining three rats, mild vacuolar degenerative changes (grade +1) were observed in the hepatocytes' cytoplasm (Figure 1D).

**Kidneys histopathological Results:** The tissue structures of the kidneys were normal in the control and saffron groups. The proximal tubules had light eosin-stained cytoplasm with the spherical and vesicular nuclei in the center of the cells. The brush border of the cells was clear in the tubules (Figure 2A). In oxymetholone group, the renal tubules showed degenerative changes and necrosis, including cell swelling and cytoplasmic vacuolation in the epithelial cells. In the necrotic tubules, deep eosin-stained cytoplasm, pyknotic nuclei and in some samples, karyolysis were observed. The brush borders of the proximal tubules were destroyed. Multifocal

accumulations of lymphocytes were observed in various parts of the kidneys (Figures 2B & 2C). In the treatment group (oxymetholone+saffron), degenerative changes and cell necrosis were significantly lower than those found in the oxymetholone group. Lymphocytic interstitial nephritis was present, although not as pronounced in some of the samples (Figure 2D).

## Discussion

Anabolic-Androgenic Steroids (AAS), derivatives of testosterone, are synthetic hormones that have such effects as promoting muscle growth and male secondary sex characteristics. They are used through oral, intradermal, and intramuscular formulations in bodybuilders and therapeutically in some medical conditions. Some athletes use AAS drugs for improving performance through increasing bone mineral density and muscle growth, associated with the hypertrophy of types I and II muscle fibers. This drug promotes muscle strength in the short-term following its administration [16, 17]. The therapeutic doses of AAS are used to treat some medical conditions, such as dysfunction of the reproductive system [16], and as replacements for hormone therapy in hypogonadism and aging. This drug is also used in the management of some diseases that cause muscle wasting, such as those seen in AIDS victims, cancer, intensive burns, chronic renal failure, and pulmonary diseases [17].

The abuse of AAS can have numerous side effects, such as immunologic dysfunction, hepatotoxicity, renal failure, osteoporosis, breast cancer, anemia, cardiovascular toxicity, unexpected cardiac death in chronic users, myocardial ischemia secondary to hematological disorders, atherosclerosis, and vasospasms [16-19]. The AAS abuse, as reported in a bodybuilder, has caused cholestatic disease and acute kidney injury, secondary to bile acid nephropathy [20]. This is a clear example of hepato-renal syndrome manifested as combined liver and kidney disorders [20]. Some researchers suggest that AAS at high concentrations can cause direct renal toxicity due to interstitial and glomerular damages [21]. Johnson et al. have reported Hepatocellular Carcinoma (HCC) in four patients with aplastic anemia after long-term therapy with AAS [22]. This condition can lead to tumor growth subsequent to metastatic cancer originated from stem cells in other organs [23].

Examples of AAS formulation include mestrolone, mestanolone, methenolone, clostebol, and oxymetholone, each causing different pathological consequences. Mestrolone, mestanolone, and methenolone can induce excessive mineralocorticoid biosynthesis, resulting in

hypertension and cardiovascular conditions. Clostebol and oxymetholone may cause metabolic disorders, such as adrenal hyperplasia via suppression of corticosteroid production [17]. Further, oxymetholone may also have therapeutic benefits by enhancing platelets' function. However, it can also have adverse effects, including redox imbalance, impaired angiogenesis, and cardiomyocyte apoptosis [19]. In addition, oxymetholone has androgenic effects, manifesting as acne, hair loss, and hirsutism [1]. It may induce metabolic disorders [17], severe damages to the liver, and hepatotoxicity [1, 5]. The adverse effects depend on the dosage, frequency and method of use [16] while the negative effects of AAS abuse are manifested as abnormalities in lipid metabolism, liver function, and hormone levels. These can return to normalcy after one year of AAS discontinuation [24]. Selective Androgen Receptor Modulators (SARMs) act as agonists in anabolic tissues like muscle and bone with little or no activation of androgenic receptors in the prostate, heart, and/or liver. The non-steroidal SARMs are safer than AAS due to their reduced adverse androgenic effects and are recognized as favorable choices for the treatment of muscle-wasting diseases [17].

The current study evaluated the effects of saffron on liver and kidneys degenerations, induced by oxymetholone (50 mg/rat). Gross hepatomegaly occurred in the rats that were treated with oxymetholone, suggesting that this drug can cause hepatomegaly at high doses in less than a year. The reason for hepatomegaly appears to be hepatic centrilobular hypertrophy and proliferation of smooth endoplasmic reticulum. This pathologic change was also reported by Miyawaki et al. [25] in the hepatomegaly induced by clobazam after a 4-week treatment in male rats. These authors suggested that hepatomegaly was mainly related to microsomal enzyme initiation, associated with the upregulation of some genes. Oxidative stress is also believed to be an important factor for the active cell proliferation and hepatomegaly observed in such cases [25]. No considerable gross changes were observed in the kidneys of the rats in the oxymetholone group. The histopathologic results from the oxymetholone group showed vacuolar degenerations and necrosis in the liver and kidneys. Also, interstitial nephritis was observed in the kidneys.

The current study did not detect hepatocellular carcinoma or adenoma in the oxymetholone group. A likely reason may be that our study was completed in a relatively short duration. Also, we did not observe any hepatic inflammation and bile accumulation with oxymetholone at a high dose given in one month. This implies a higher safety margin for oxymetholone than for other



**Table 1.** Mean $\pm$ SE for the grades of hepatic degenerative changes.

Groups	Grades (Mean $\pm$ SE)
Oxymetholone only	2.33 $\pm$ 0.32 <sup>a</sup>
Treatment (Oxymetholone+Saffron)	0.50 $\pm$ 0.21 <sup>b</sup>

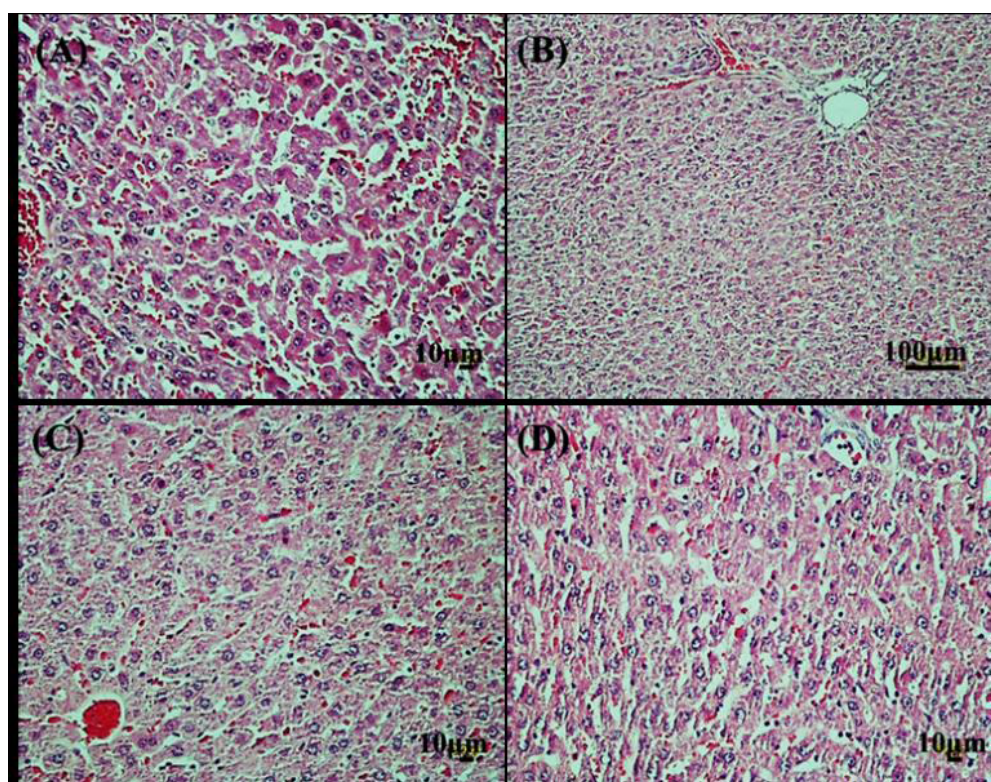
Superscript alphabets (a, b) in the right column indicate significant difference between the groups ( $P < 0.05$ ).

The cellular structures in the liver tissue samples from the control and saffron groups were normal.

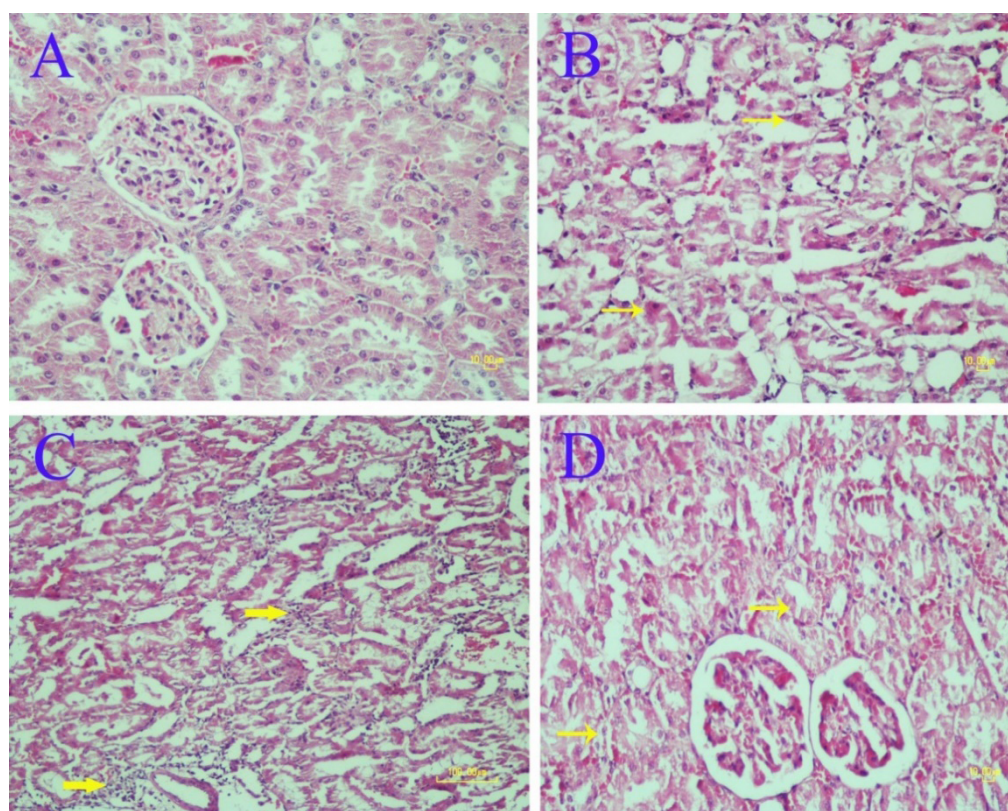
strong anabolic-androgenic steroids. Administration of AAS may increase the risk of injury in some organs by inducing oxidative stress [26] due to the mitochondrial degeneration in hepatocytes in response to the increased levels of Reactive Oxygen Species (ROS) in the tissues. This occurs due to the activation of androgen receptors, and increased carnitine palmitoyltransferase-1 activity, which is a rate-limiting enzyme in the mitochondrial processing of fatty acid  $\beta$ -oxidation. This process also leads to oxidative stress in hepatic cells as one of the side effects of AAS. This explains why some antioxidants can protect the liver against the hepatotoxicity induced by anabolic-androgenic steroids [27]. Therefore, it necessitates the use of antioxidants, such as vitamin E to prevent the oxidative damages, such as nephrotoxicity

in different tissues [28]. In a study conducted by Pagonis et al. [29], it was shown that using B complex vitamins combined with polyunsaturated phospholipids produced hepatoprotective effects against AAS-induced tissue degeneration [29]. That is because of the antioxidant activities of vitamin B group against the oxidative stress caused by AAS abuse.

Saffron is used for its pleasant aroma and as an antioxidant with useful properties, such as sedative, hypotensive, immunomodulating, and stimulating effects on respiration [7, 14]. Saffron induces anti-cancer activity and regulates the liver enzymes' level [30]. It can be used to treat digestive disorders due to its properties including antioxidant, free radicals scavenging, anti-inflammatory,

**Figure 1.** The cellular structures in the liver tissue

A: In control group shows normal structure; B) and C: In oxymetholone group with severe (grade: +3) and moderate (grade: +2) cell swelling and vacuolation; D: In saffron treated group shows mild degenerative changes (grade: +1) (HE staining).



**Figure 2.** The cellular structures in the kidney tissue

A: Normal structure of kidney in the control group; B and C: The oxymetholone group shows severe necrotic changes (thin arrows) and interstitial nephritis (thick arrows); D: The saffron treated group shows reduction of vacuolar degenerative (arrows) changes and necrosis.

and preventing lipid peroxidation. It may offer therapeutic effects in hepatotoxicity, fatty liver, stomach cancer, peptic ulcer, colon cancer, ulcerative colitis, diabetes, and pancreatic cancer [31]. In a previous study, it was suggested that the ethanolic extract of saffron at 40 mg/kg/day may impart hepatoprotective effects on the liver in diabetic rats. These protective properties were attributed to the antioxidant effects of saffron, based on such biochemical parameters as malondialdehyde, superoxide dismutase, and catalase levels, as indications of free radicals scavenging and anti-oxidative activities [32].

The biological effects of saffron are believed to be due to its active constituents, including crocetin, picrocrocetin, and safranal, which are responsible for its pleasant aroma. Crocin, an ester of crocetin, is a water-soluble carotenoid that constitutes a major part of saffron. Many carotenoid and flavonoid compounds have been isolated from saffron are also found in the saffron plant [14]. Carotenoids can prevent toxicity and cancer, with such mechanisms as antioxidant activity, enhancement of cell differentiation, and immune system modulation [10].

Hariri et al. evaluated the mitigating influence of safranal in preventing the negative effects of diazinon, a neurotoxic organophosphate compound, on the levels of specific biomarkers and enzymes [33]. For its assessment, safranal (0.025, 0.05, and 0.1 ml/kg), crocin (50, 100, and 200 mg/kg), and vitamin E (200 IU/kg) were injected intraperitoneally in groups of rats, either alone or combined with diazinon three times a week for one month. It was demonstrated that safranal and crocin resulted in protective effects and prevented the increase in some enzymes and biochemical markers. Also, it was suggested that crocin had better effects than that of safranal [33]. The hepatoprotective effects of crocetin, as a major Chinese herbal medicine, against oxidative damages in rats have been demonstrated earlier [34]. Crocetin has antioxidant properties by increasing the oxygen transport in plasma, tissues, and cells [35]. Therefore, saffron can protect against oxidative damages due to its major constituent, crocetin.

## Conclusions

The current study demonstrated that a one-month treatment with saffron at a dose of 40 mg/kg/day resulted in a



significant reduction in the hepatic and renal degenerative changes caused by oxymetholone. The antioxidant properties of saffron can reduce degenerative changes, based on the potential mechanism of scavenging free radicals in the liver and kidneys. To the best of our knowledge, the traditional use of saffron can be useful and protective against oxidative damages caused in the liver and kidneys by certain toxic agents, such as oxymetholone.

## Ethical Considerations

### Compliance with ethical guidelines

All animals received humane care in compliance with the Guide for Care and Use of Laboratory Animals published by the National Institutes of Health (NIH publication No. 85-23, revised 1985). The study was approved by the Institutional Animal Care and Use Committee of Bahonar Veterinary School in Kerman, (Registration#: IR.UK.1396.127).

### Funding

This research was financially supported by a grant from the Research Council of Shahid Bahonar University in Kerman, Iran.

### Author's contributions

Writing – review & editing: Reza Kheirandish and Shahrzad Azizi; Methodology: Mehdi Saberi; Experimental procedures: Reza Khakdan; Writing – original draft: Zahra Kordzadeh Kermani.

### Conflict of interest

The authors declared no conflict of interest.

### Acknowledgments

The authors would like to thank Mr. Saeed Hassanzadeh for preparing tissue sections for light microscopic analyses.

## References

- [1] Pavlatos AM, Fultz O, Monberg MJ, Vootkur A. Review of oxymetholone: A 17 $\alpha$ -alkylated anabolic androgenic steroid. *Clin Ther*. 2001; 23(6):789-801. [DOI:10.1016/S0149-2918(01)80070-9]
- [2] Kratena N, Biedermann N, Stojanovic B, Göschl L, Weil M, Enev VS, et al. Synthesis of a human long-term oxymetholone metabolite. *Steroids*. 2019; 150:108430. [DOI:10.1016/j.steroids.2019.108430] [PMID]
- [3] Madrakian T, Afkhami A, Rahimi M, Ahmadi M, Soleimani M. Preconcentration and spectrophotometric determination of oxymetholone in the presence of its main metabolite (mestanolone) using modified maghemite nanoparticles in urine sample. *Talanta*. 2013; 115:468-73. [DOI:10.1016/j.talanta.2013.05.056] [PMID]
- [4] Rohani A, Imanipour V. Effects of oxymetholone on hematological and liver factors in the male bodybuilder's serum. *Procedia Soc Behav Sci*. 2009; 1(1):2814-6. [DOI:10.1016/j.sbspro.2009.01.500]
- [5] Nejati V, Zahmatkesh E, Babaei M. Protective Effects of royal jelly on oxymetholone-induced liver injury in mice. *Iran Biomed J*. 2016; 20(4):229-34. [DOI:10.7508/ibj.2016.04.007] [PMID] [PMCID]
- [6] Yuan Y, Che L, Qi C, Meng Z. Protective effects of polysaccharides on hepatic injury: A review. *Int J Biol Macromol*. 2019; 141:822-30. [DOI:10.1016/j.ijbiomac.2019.09.002] [PMID]
- [7] Milajerdi A, Jazayeri S, Bitarafan V, Hashemzadeh N, Shirzadi E, Derakhshan Z, et al. The effect of saffron (*Crocus sativus* L.) hydro-alcoholic extract on liver and renal functions in type 2 diabetic patients: A double-blinded randomized and placebo control trial. *J Nutr Intermed Metab*. 2017; 9:6-11. [DOI:10.1016/j.jnim.2017.07.002]
- [8] Co I, Gunnerson K. Emergency department management of acute kidney injury, electrolyte abnormalities, and renal replacement therapy in the critically ill. *Emerg Med Clin North Am*. 2019; 37(3):459-71. [DOI:10.1016/j.emc.2019.04.006] [PMID]
- [9] Göcze I, Wiesner C, Schlitt HJ, Bergler T. Renal recovery. *Best Pract Res Clin Anaesthesiol*. 2017; 31(3):403-14. [DOI:10.1016/j.bpa.2017.08.006] [PMID]
- [10] Bolhassani A, Khavari A, Bathaie SZ. Saffron and natural carotenoids: Biochemical activities and anti-tumor effects. *Biochim Biophys Acta*. 2014; 1845(1):20-30. [DOI:10.1016/j.bbcan.2013.11.001] [PMID]
- [11] Ratheesh G, Xiao Y, Ezhilarasu H, Sadiq A, Devassy G, Tian L, et al. Nanodrug delivery system using medicinal plants. In: Sharma CP, editor. *Drug delivery nanosystems for biomedical applications*. Netherlands: Elsevier Science; 2018. [DOI:10.1016/B978-0-323-50922-0.00016-X]
- [12] Daley DK. Plant crude drugs. In: McCreath SB, Delgoda R, editors. *Pharmacognosy: Fundamentals, applications and strategy*. Netherlands: Elsevier Science; 2017. [DOI:10.1016/B978-0-12-802104-0.00006-8]
- [13] Karimi-Nazari E, Nadjarzadeh A, Masoumi R, Marzban A, Mohajeri SA, Ramezani-Jolfaie N, et al. Effect of saffron (*Crocus sativus* L.) on lipid profile, glycemic indices and antioxidant status among overweight/obese prediabetic individuals: A double-blinded, randomized controlled trial. *Clin Nutr ESPEN*. 2019; 34:130-6. [DOI:10.1016/j.clnesp.2019.07.012] [PMID]
- [14] Liakopoulou-Kyriakides M, Kyriakidis DA. Crocus sativus-biological active constituents. *Stud Nat Prod Chem*. 2002; 26(Part G):293-312. [DOI:10.1016/S1572-5995(02)80009-6]
- [15] Asbaghi O, Soltani S, Norouzi N, Milajerdi A, Choobkar S, Asemi Z. The effect of saffron supplementation on blood glucose and lipid profile: A systematic review and meta-analysis of randomized controlled trials. *Complement Ther Med*. 2019; 47:102158. [DOI:10.1016/j.ctim.2019.07.017] [PMID]

- [16] Lusetti M, Licata M, Silingardi E, Reggiani Bonetti L, Palmieri C. Pathological changes in anabolic androgenic steroid users. *J Forensic Leg Med.* 2015; 33:101-4. [DOI:10.1016/j.jflm.2015.04.014] [PMID]
- [17] Patt M, Beck KR, Di Marco T, Jäger MC, González-Ruiz V, Bocard J, et al. Profiling of anabolic androgenic steroids and selective androgen receptor modulators for interference with adrenal steroidogenesis. *Biochem Pharmacol.* 2020; 172:113781. [DOI:10.1016/j.bcp.2019.113781] [PMID]
- [18] Welder AA, Robertson JW, Melchert RB. Toxic effects of anabolic-androgenic steroids in primary rat hepatic cell cultures. *J Pharmacol Toxicol Methods.* 1995; 33(4):187-95. [DOI:10.1016/1056-8719(94)00073-D]
- [19] Seara FAC, Olivares EL, Nascimento JHM. Anabolic steroid excess and myocardial infarction: From ischemia to reperfusion injury. *Steroids.* 2020; 161:108660. [DOI:10.1016/j.steroids.2020.108660] [PMID]
- [20] Luciano RL, Castano E, Moeckel G, Perazella MA. Bile acid nephropathy in a bodybuilder abusing an anabolic androgenic steroid. *Am J Kidney Dis.* 2014; 64(3):473-6. [DOI:10.1053/j.ajkd.2014.05.010] [PMID]
- [21] Parente Filho SLA, Gomes PEA de C, Forte GA, Lima LLL, Silva Júnior GB da, Meneses GC, et al. Kidney disease associated with androgenic-anabolic steroids and vitamin supplements abuse. *Nefrologia.* 2020; 40(1):26-31. [DOI:10.1016/j.nefro.2019.06.003] [PMID]
- [22] Johnson FL, Lerner KG, Siegel M, Feagler JR, Majerus PW, Hartmann JR, et al. Association of androgenic-anabolic steroid therapy with development of hepatocellular carcinoma. *Lancet.* 1972; 300(7790):1273-6. [DOI:10.1016/S0140-6736(72)92649-9]
- [23] Ji J, Wang XW. Clinical implications of cancer stem cell biology in hepatocellular carcinoma. *Semin Oncol.* 2012; 39(4):461-72. [DOI:10.1053/j.seminoncol.2012.05.011] [PMID] [PMCID]
- [24] Urhausen A, Torsten A, Wilfried K. Reversibility of the effects on blood cells, lipids, liver function and hormones in former anabolic-androgenic steroid abusers. *J Steroid Biochem Mol Biol.* 2003; 84(2-3):369-75. [DOI:10.1016/S0960-0760(03)00105-5]
- [25] Miyawaki I, Matsumoto I, Horie H, Inada H, Kimura J, Funabashi H, et al. Toxicological approach for elucidation of clobazam-induced hepatomegaly in male rats. *Regul Toxicol Pharmacol.* 2011; 60(3):323-31. [DOI:10.1016/j.yrtph.2011.04.009] [PMID]
- [26] Arazi H, Mohammadjafari H, Asadi A. Use of anabolic androgenic steroids produces greater oxidative stress responses to resistance exercise in strength-trained men. *Toxicol Rep.* 2017; 4:282-6. [DOI:10.1016/j.toxrep.2017.05.005] [PMID] [PMCID]
- [27] Bond P, Llewellyn W, Van Mol P. Anabolic androgenic steroid-induced hepatotoxicity. *Med Hypotheses.* 2016; 93:150-3. [DOI:10.1016/j.mehy.2016.06.004] [PMID]
- [28] Derakhshanfar A, Bidadkosh A, Kazemina S. [Vitamin E protection against gentamicin-induced nephrotoxicity in rats: A biochemical and histopathologic study (Persian)]. *Iran J Vet Res.* 2007; 8(3):231-8. [sid.ir/en/Journal/ViewPaper.aspx?ID=85255](http://sid.ir/en/Journal/ViewPaper.aspx?ID=85255)
- [29] Pagonis TA, Koukoulis GN, Hadjichristodoulou CS, Toli PN, Angelopoulos NV. Multivitamins and phospholipids complex protects the hepatic cells from androgenic-anabolic-steroids-induced toxicity. *Clin Toxicol.* 2008; 46(1):57-66. [DOI:10.1080/15563650701590910] [PMID]
- [30] Milajerdi A, Djafarian K, Hosseini B. The toxicity of saffron (*Crocus sativus* L.) and its constituents against normal and cancer cells. *J Nutr Intermed Metab.* 2016; 3:23-32. [DOI:10.1016/j.jnim.2015.12.332]
- [31] Khorasany AR, Hosseinzadeh H. Therapeutic effects of saffron (*Crocus Sativus* L.) in digestive disorders. *Iran J Basic Med Sci.* 2016; 19(5):455-69. [PMCID]
- [32] Rahbani M, Mohajeri D, Rezaie A, Nazeri M. Protective effect of ethanolic extract of saffron (dried stigmas of *Crocus sativus* L.) on hepatic tissue injury in streptozotocin-induced diabetic rats. *J Anim Vet Adv.* 2012; 11(12):1985-94. [DOI:10.3923/javaa.2012.1985.1994]
- [33] Hariri AT, Moallem SA, Mahmoudi M, Memar B, Hosseinzadeh H. Sub-acute effects of diazinon on biochemical indices and specific biomarkers in rats: Protective effects of crocin and safranin. *Food Chem Toxicol.* 2010; 48(10):2803-8. [DOI:10.1016/j.fct.2010.07.010] [PMID]
- [34] Tseng TH, Chu CY, Huang JM, Shioh SJ, Wang CJ. Crocetin protects against oxidative damage in rat primary hepatocytes. *Cancer Lett.* 1995; 97(1):61-7. [DOI:10.1016/0304-3835(95)03964-X]
- [35] Wilkins ES, Wilkins MG. Studies of the mechanism of action of the carotenoid crocetin. *Experientia.* 1979; 35(1):84-6. [DOI:10.1007/BF01917893] [PMID]

This Page Intentionally Left Blank